

# Analysis of the Prevalence of Lumbar Annular Tears in Adult Patients Using Magnetic Resonance Imaging Data

Mohammad Davoudi<sup>1</sup>, Rahman S. Zabibah<sup>2</sup>, Andrés Alexis Ramírez-Coronel<sup>3,4,5,6</sup>, Ali Hussein Demin Al-Khafaji<sup>7\*</sup>, Acim Heri Iswanto<sup>8</sup>, Gholamreza Ataei<sup>9\*</sup>, Elham Yousefi<sup>10</sup>, Fatemeh Zahra Nosrati<sup>9</sup>, Danial Fazilat-Panah<sup>11</sup>

<sup>1</sup> Department of Medical Radiation Engineering, Central Tehran Branch, Islamic Azad University, Tehran, Iran

<sup>2</sup> Medical Laboratory Technology Department, College of Medical Technology, The Islamic University, Najaf, Iraq

<sup>3</sup> Azogues Campus Nursing Career, Health and Behavior Research Group (HBR), Psychometry and Ethology Laboratory, Catholic University of Cuenca, Ecuador

<sup>4</sup> Doctorate in Psychology, University of Palermo, Buenos Aires, Argentina

<sup>5</sup> Research group in Educational Statistics, National University of Education, Ecuador

<sup>6</sup> Epidemiology and Biostatistics Research Group, CES University, Medellin, Colombia

<sup>7</sup> Department of Laboratories Techniques, Al-Mustaqbal University College, Babylon, Hillah, Iraq

<sup>8</sup> Department of Public Health, Faculty of Health Science, University of Pembangunan Nasional Veteran Jakarta, Jakarta, Indonesia

<sup>9</sup> Radiotherapy Physics Department, Babolsar Oncology Hospital, Babolsar, Iran

<sup>10</sup> Department of Radiology, Babol University of Medical Sciences, Babol, Iran

<sup>11</sup> Cancer Research Center, Babol University of Medical Sciences, Babol, Iran

\*Corresponding Authors: Ali Hussein Demin Al-Khafaji, Gholamreza Ataei  
Email: [ali.hussein@uomus.edu.iq](mailto:ali.hussein@uomus.edu.iq), [Golamrezaatae@yahoo.com](mailto:Golamrezaatae@yahoo.com) Received: 28 November 2022 / Accepted: 01 January 2023

## Abstract

**Purpose:** This study aimed to evaluate the lumbar annular tears prevalence regarding the patient's history factors, and Magnetic Resonance Imaging (MRI) recorded data.

**Materials and Methods:** In this study, 218 patients (106 men and 112 women) were evaluated; 136 cases (63 men and 73 women, 20-80 years, mean: 45.4±14.8 years) with Lower Back Pain (LBP) and High-Intensity Zone (HIZ) were diagnosed based on MR images. The diagnosed annular tears from the MRI data, Body Mass Index (BMI, kg/m<sup>2</sup>), and physical activity of the patients were recorded, and the prevalence of lumbar annular tears was evaluated regarding the mentioned parameters.

**Results:** The prevalence of annular tears was 31.6% at L5/S1 (43/136 patients), 43.4% at L4/L5 (59/136 patients), 16.9% at L3/L4 (23/136 patients), 4.4% at L2/L3 (6/136 patients), and 3.7% at L1/L2 spinal disc space (5/136 patients). Most patients with annular tears had LBP (>60%). Based on the patient's history, 25% of patients had BMI above 30, 8.8% had post-traumatic history, 15.4% had a history of falling down, 19.1% had slipped down history, 16.2% were athletes, and 15.4% performed heavy work.

**Conclusion:** The prevalence of lumbar annular tears was higher in patients having LBP and a BMI over 30, which should be considered possible risk factors. This study demonstrated that annular tears are more likely to occur in lower lumbar discs, especially in L4/L5 and L5/S1 discs.

**Keywords:** Prevalence; Annular Tears; High-Intensity Zone; Low Back Pain; Magnetic Resonance Imaging.

## 1. Introduction

Approximately 80% of the population will suffer from Lower Back Pain (LBP) in their life span [1, 2]. Discogenic LBP is the most prevalent type of chronic LBP associated with disc degeneration, particularly annular fissures reaching the outer annulus [3–5]. Increased disc pressure can evoke discogenic pain by stimulating nerve endings sensitized by inflammatory mediators [6].

Magnetic Resonance Imaging (MRI) is a useful diagnostic tool to evaluate central nervous systems such as disc herniation, lateral canal stenosis, post-operative root fibrosis, and precise localization of intervertebral disc changes [7–10]. Furthermore, MRI does not utilize ionizing radiations and therefore lacks radiation toxicities concern [11,12]. Annular tears (also called annular fissures) can be detected using MRI as the High-Intensity Zone (HIZ) and hyperintense on T2 weighted images [8,13,14]. Several factors, such as Body Mass Index (BMI) and physical activity, can affect the lumbar annular tears [15–18]. It was reported that a strong correlation exists between BMI values and the prevalence of annular tears in adult patients [15].

Several studies reported the prevalence of annular tears in different regions of the spine [6, 13, 15, 16, 19]. However, as a common disease, it needs to be evaluated and reported in different populations in various geographical regions. Following our search, few studies reported the prevalence of annular tears in Iran. Thus, the current study aimed to present the relevant data of lumbar annular tears in adult patients using MRI data of patients referred to general hospitals in Babol, Iran. We also assessed and analyzed the prevalence of disk annular tears regarding the patient's history and physical parameters such as BMI, LBP, falling down, slipping down, being an athlete, and traumatic history. It should be noted that some of our evaluated factors have not been considered in previous studies.

## 2. Materials and Methods

### 2.1. Patients

Sagittal and transverse lumbar spine T1- and T2-weighted MR images of 218 adult patients (106 men and 112 women) suspected of lumbar spine diseases were evaluated. Patients with a history of surgery,

radiotherapy, and chronic self-defense diseases were excluded from our study. The age range of the investigated patients was 20 to 80 years (mean= 45.4 years and standard deviation= 14.8 years).

This cross-section study was approved by the Ethics Committee and National Research Ethics Board. Written informed consent was obtained from all participants, and the patients were informed that the study protocol had no invasive procedure.

### 2.2. Investigated Parameters

In the first step, the history of patients, including BMI ( $\text{kg/m}^2$ ), LBP, falling down, slipping down, being an athlete, and traumatic history was recorded by gathering the questionnaires. In the next step, MR images and reports were evaluated, and the sites of lumbar annular tears were obtained and recorded for each patient.

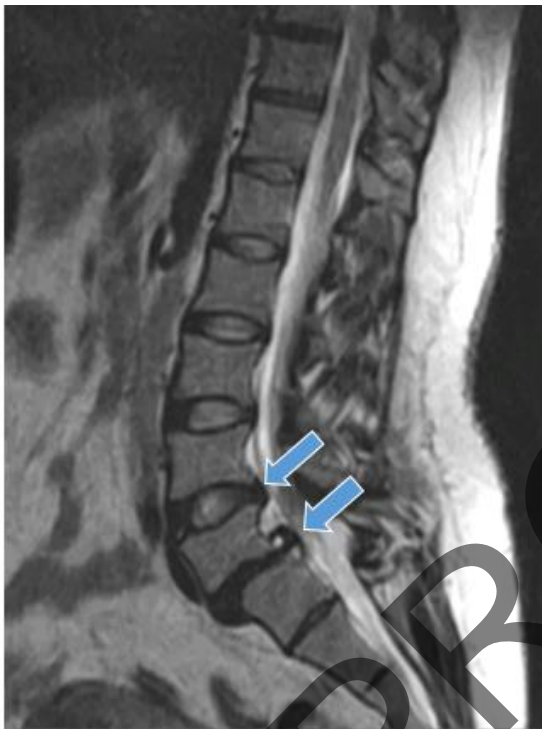“Traumatic history” refers to traffic accidents or each post-traumatic hit [20]. The meaning of LBP was resistant pain for over 6 months that was aggravated by sitting for a long time, standing from a sitting position, lifting and forward bending of the low back, and relieved by lying supine. “Heavy work” refers to lifting or moving heavy objects and working for a long time, leading to back pain. Before completing the questionnaires, all of the above explanations were clarified to patients [21].

### 2.3. MR Imaging Protocol

A lumbar spine MRI of the patients was performed in three medical imaging centers with 0.35 Tesla (12 patients), 0.5 Tesla (18 patients), and 1.5 Tesla (188 patients) field strengths and a resolution of  $128 \times 128$ ,  $256 \times 256$ , and  $256 \times 256$  pixels, respectively. All the images were taken with spin-echo pulse sequences but various Time Echo (TE) and Repetition Time (TR) regarding the scanner type and desired image weighting. All patients were scanned in the supine position, and sagittal and axial T1 and T2-weighted images were obtained. A minimum of 16 sagittal slices with a resolution of 3 mm were obtained for each patient. All of the MR images were independently evaluated by three radiologists (with 7, 12, and 15 years of experience) that blinded to the patient's information.

HIZ of the lumbar intervertebral disc defines as a high-intensity signal located in the posterior annulus

fibrosus on T2-weighted MRI and surrounded by the low-intensity signal of the annulus fibrosus [22]. Figure 1 represents an example of HIZ in one T2-weighted slice for one of the patients. The criteria for an HIZ included a high-intensity signal located in the posterior annulus fibrosus, clearly dissociated from the signal of the nucleus pulposus and appreciably brighter than that of the nucleus pulposus. To better diagnose annular tears against the calcified tissue, both T1- and T2-weighted images were evaluated.



**Figure 1.** Example of HIZ (arrow) in T2-weighted MRI sagittal images for one of the patients

#### 2.4. Statistical Analysis

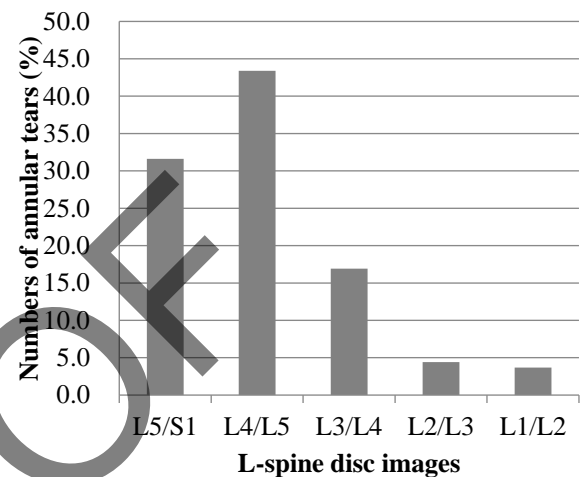
All statistical analyses were performed using the SPSS software package, version 16 (IBM, USA). The patients were divided into 6 groups based on their history parameters. The prevalence of lumbar annular tears was compared among the groups by Kruskal-Wallis statistical test. The level of statistical significance was considered at 5%.

### 3. Results

In this study, 218 patients have been evaluated; 136 cases with annular tears were diagnosed based on their

MR images. Sixty-three of these patients were men (46.3%), and 73 were women (53.7%).

Figure 2 illustrates the prevalence of lumbar annular tears in various sites of the assessed patients. It was observed that the highest prevalence was associated with L4/L5 with 43.4% (59/136 patients). Other diagnosed problems included disc herniation at 38.9% (53/136), spondylolisthesis at 8% (11/136), and spinal canal stenosis at 53.6% (73/136).



**Figure 2.** Prevalence of annular tears (%) in various lumbar spine joints

The prevalence of patients with lumbar annular tears (%) divided by their various historical factors is reported in Figure 3. The patients were divided into different groups by their history factors and compared to each other, showing significant differences. Patients with BMI above 30 had a statistically higher prevalence of annular tears compared to other factors ( $P < 0.03$ ). The second important risk factor is the history of slip-down, and the least important factor is related to the patients after the trauma. In these patients, the main problem is usually bone fracture, hemorrhage, and tissue damage. Therefore, we did not expect patients with a history of trauma to have a high amount of annular tears. The LBP is also presented in Figure 3. It is seen that 84 (61.8%) patients had LBP, which was associated with the above histories.

Some of the investigated patients had annular tears in two discs, including 23.6% in L5/S1 & L4/L5 disks, 13.9% in L4/L5 & L3/L4, 13.9% in L3/L4 & L2/L3, and 1.08% in L2/L3 & L1/L2.

To evaluate the incidence of annular tears regarding the patient's age, the MR images of the patients under

and over 50 years were compared. The incidence of radiating tears in the posterior annulus in the older age group was more significant than other types of tears (Peripheral and Circumferential tears), with degeneration of the nucleus pulposus in a way that 32.6% of patients in the older group showed nuclear degeneration compared to 5.1% of those under 50 years.

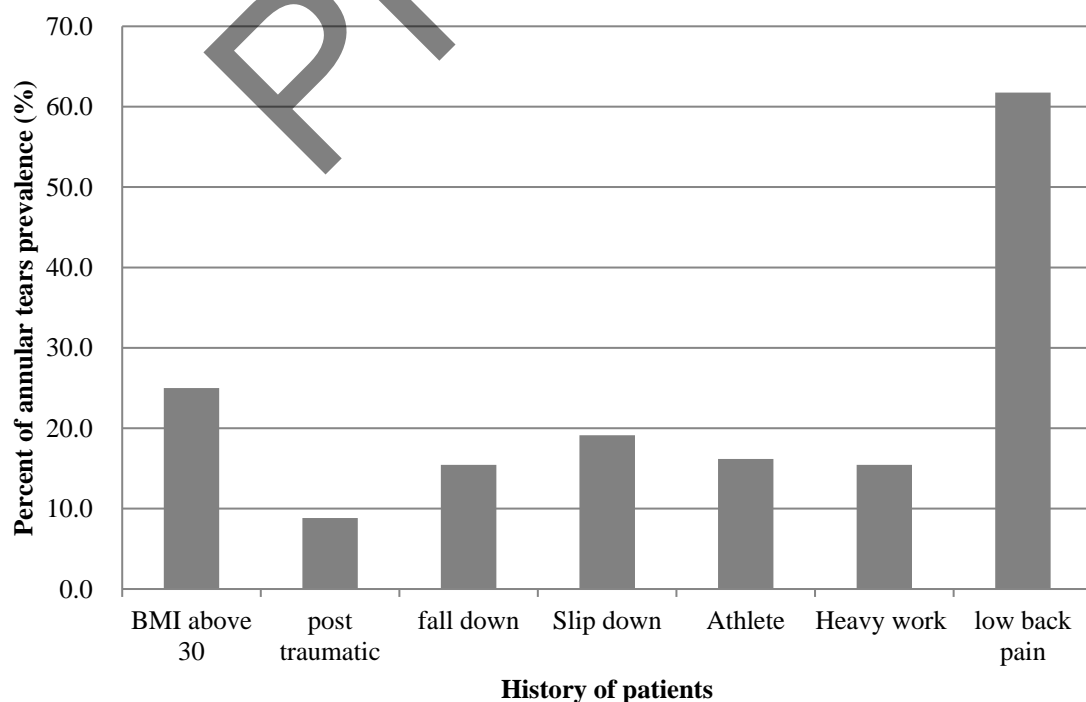
#### 4. Discussion

We have assessed lumbar annular tears' prevalence for patients with various disease histories and physical factors. Several similar studies have reported the prevalence of annular tears in different regions of the spine [6, 13, 15, 16, 19]. To obtain adequate information about this disease, one must evaluate and report the prevalence in other populations of various geographical regions. Therefore, we tried to report the prevalence in adult patients using MRI data of patients referred to general hospitals in Babol, Iran. Notably, there is no study evaluating the disease prevalence for patients with different referring reasons to MRI and disease history.

The cervical and lumbar spine are among the first areas of the human body to show demonstrable imaging evidence of degenerative joint disease [19, 23]. We

considered HIZs in T2-weighted MRI as an indicator of annular tears. Many studies have suggested that HIZ can be associated with LBP and annular tears [24–28]; however, there are also several studies reported that this typical sign described by Aprill and Bogduk [24] is not a reliable diagnostic indicator [5, 8, 22]. Therefore, the diagnostic value of HIZ for LBP and annular tears on lumbar MR images has always been under discussion [25, 29, 30]. We assumed that an HIZ illustrated on only the T2-weighted obtained images often represents an annular tear, but an HIZ on both T1- and T2- weighted images indicates calcified tissue [5,18,19]. In this regard, we also used T1-weighted images to diagnose annular tears against the calcified tissue better.

Wang *et al.* [18] suggested that HIZ can indicate some part of the disc degeneration history. Age-related histological changes can be observed in the lumbar disc annulus fibrosis [31]. We did not consider the patient's age a risk factor for annular tears because it was previously reported that older patients have significantly higher risks of annular tears [6, 9, 32]. Therefore, we tried to evaluate other factors, although, our results showed that the incidence of radiating tears in the posterior annulus in the older age group was more remarkable than other types of tears (Peripheral and



**Figure 3.** Prevalence of annular tears (%) regarding patients' historical and physical parameters



Circumferential tears), with the presence of degeneration of the nucleus pulposus.

The relationship between cervical/lumbar spine abnormalities and LBP was reported frequently in previous studies as a controversial subject [3, 26, 27, 29, 30]. Annular tears were frequently diagnosed on MR images in patients having LBP or brachialgia [3]. The present study found that most of the patients having annular tears on lumbar MR images suffer from LBP. In fact, the LBP is one of the main primary signs for patients referred to MR imaging of the lumbar spine. There was LBP in 84% of patients referred to lumbar MR imaging in our study. The annulus fibrosis is innervated by the recurrent meningeal nerve and by the small branches from the ventral ramus of the somatic nerve [32]. Therefore, the annular tear can be responsible for LBP.

The annular tears may occur without LBP. The prevalence of annular tears in the lumbar spine of the symptom-free population was reported in several studies using MRI data [19,33–35]. The reported prevalence of posterior annular tears at autopsy in the asymptomatic population was 40% for patients between 50 and 60 years and 75% for those between 60 and 70 years [35]. The lower prevalence of asymptomatic patients in our study may be related to the lower age of our patients. Jensen *et al.* [33] found 14% of annular defects in 98 asymptomatic volunteers examined with axial and sagittal T1- and T2-weighted MR images. Stadnik *et al.* [34] found 28 annular tears in 20 patients (56%) of 36 asymptomatic volunteers using sagittal gadolinium-enhanced T1- and T2-weighted images. The differences in asymptomatic patients with annular tears reported in previous studies can be related to the different age ranges of the evaluated patients. As it was mentioned, the prevalence of asymptomatic patients increases with age.

As we expected, there was no significant difference in the prevalence of annular tears between males and females. Our findings revealed that annular tears occurred mostly at L4/L5 and L5/S1. The results of the present study are in accordance with previous studies in different patient populations, demonstrating that the incidence rate of annular tears is higher at the lower disc levels [6, 22, 26]. Furthermore, it was reported that the incidence of LBP was higher when the annular tears occurred at the lower disc levels (for example, L4/5 or L5/S1) or when multiple annular tears were diagnosed [18]. This research observed that radiating annular imperfections are closely related to nucleus pulposus

degeneration and are often in the lower lumbar spine or the posterior annulus.

Among the evaluated history factors, BMI was the most common reason for LBP, which can be a sign of annular tears. A BMI higher than 30 was statistically the most prevalent sign in patients with lumbar annular tears. The relationship between the incidence of annular tears and BMI was previously reported [15]. It must also be mentioned that generally, patients with this case must be assessed along with other historical factors such as falling down and slipping down. Being overweight can be a risk factor for lumbar diseases such as annular tears [17, 36]; hence, reducing body weight effectively reduces the risk of annular tears [17, 36].

The present study was performed on patients with annular tears in the lumbar region. Similar studies can be conducted on the cervical and thoracic spine. Furthermore, other historical factors, such as disease history, can be considered, and the correlation between the history factors' values and the prevalence of annular tears can be assessed in future studies.

## 5. Conclusion

The prevalence of annular tears regarding different historical factors was evaluated in the current study. The LBP and BMI over 30 had the most prevalence of lumbar annular tears and can be considered possible risk factors. This study demonstrated that annular tears are more likely to occur in lower lumbar discs, especially in L4/L5 and L5/S1 discs. These results can be helpful to understand better the indicators and causes of annular tears and LBP following the patient's history.

## Acknowledgments

All the managers and staff of the Departments of Medical Imaging and radiologists for their efficient support in this study.

## References

- 1- Aimin Wu *et al.*, "Global low back pain prevalence and years lived with disability from 1990 to 2017: estimates from the Global Burden of Disease Study 2017." *Annals of translational medicine*, Vol. 8 (No. 6), (2020).

- 2- Yin-gang Zhang, Tuan-mao Guo, Xiong Guo, and Shi-xun Wu, "Clinical diagnosis for discogenic low back pain." *International journal of biological sciences*, Vol. 5 (No. 7), p. 647, (2009).
- 3- Jan Willem Kallewaard *et al.*, "Discogenic low back pain." *Evidence-Based Interventional Pain Medicine: According to Clinical Diagnoses*, pp. 107-22, (2011).
- 4- Richard Derby, Byung-Jo Kim, Yung Chen, Kwan-Sik Seo, and Sang-Heon Lee, "The relation between annular disruption on computed tomography scan and pressure-controlled diskography." *Archives of physical medicine and rehabilitation*, Vol. 86 (No. 8), pp. 1534-38, (2005).
- 5- Zhi Shan, Huanhuan Chen, Junhui Liu, Hong Ren, Xuyang Zhang, and Fengdong Zhao, "Does the high-intensity zone (HIZ) of lumbar intervertebral discs always represent an annular fissure?" *European radiology*, Vol. 27 (No. 3), pp. 1267-76, (2017).
- 6- Michael T Modic and Jeffrey S Ross, "Lumbar degenerative disk disease." *Radiology*, Vol. 245 (No. 1), pp. 43-61, (2007).
- 7- Victor Haughton, "Imaging intervertebral disc degeneration." *Jbjs*, Vol. 88 (No. suppl\_2), pp. 15-20, (2006).
- 8- Pokhraj Suthar, Rupal Patel, Chetan Mehta, and Narrotam Patel, "MRI evaluation of lumbar disc degenerative disease." *Journal of clinical and diagnostic research: JCDR*, Vol. 9 (No. 4), p. TC04, (2015).
- 9- Pang Hung Wu, Hyeun Sung Kim, and Il-Tae Jang, "Intervertebral disc diseases PART 2: a review of the current diagnostic and treatment strategies for intervertebral disc disease." *International journal of molecular sciences*, Vol. 21 (No. 6), p. 2135, (2020).
- 10- A Splendiani *et al.*, "Imaging of post-operative spine in intervertebral disc pathology." *Musculoskeletal surgery*, Vol. 101 (No. 1), pp. 75-84, (2017).
- 11- Mohammad Davoudi and Shaghayegh Lotfian Ahangarkolaei, "Image optimization and reduction of radiation dose in CT of the paranasal sinuses." *Biomedical Physics & Engineering Express*, Vol. 6 (No. 4), p. 045021, (2020).
- 12- Ali Tarighatnia, Gurkaran Johal, Ayuob Aghanejad, Hossein Ghadiri, and Nader D Nader, "Tips and Tricks in Molecular Imaging." *Frontiers in Biomedical Technologies*, Vol. 8 (No. 3), pp. 226-35, (2021).
- 13- A Sharma, T Pilgram, and FJ Wippold, "Association between annular tears and disk degeneration: a longitudinal study." *American journal of neuroradiology*, Vol. 30 (No. 3), pp. 500-06, (2009).
- 14- I Khan, R Hargunani, and A Saifuddin, "The lumbar high-intensity zone: 20 years on." *Clinical radiology*, Vol. 69 (No. 6), pp. 551-58, (2014).
- 15- Oded Hershkovich *et al.*, "Associations of body mass index and body height with low back pain in 829,791 adolescents." *American journal of epidemiology*, Vol. 178 (No. 4), pp. 603-09, (2013).
- 16- M Liuke *et al.*, "Disc degeneration of the lumbar spine in relation to overweight." *International journal of obesity*, Vol. 29 (No. 8), pp. 903-08, (2005).
- 17- Xian Xu, Xu Li, and Wei Wu, "Association between overweight or obesity and lumbar disk diseases." *Journal of Spinal Disorders and Techniques*, Vol. 28 (No. 10), pp. 370-76, (2015).
- 18- Zi-Xuan Wang and You-Gu Hu, "Factors associated with lumbar disc high-intensity zone (HIZ) on T2-weighted magnetic resonance image: a retrospective study of 3185 discs in 637 patients." *Journal of Orthopaedic Surgery and Research*, Vol. 13 (No. 1), pp. 1-6, (2018).
- 19- CW Ernst, TW Stadnik, E Peeters, C Breucq, and MJC Osteaux, "Prevalence of annular tears and disc herniations on MR images of the cervical spine in symptom free volunteers." *European journal of radiology*, Vol. 55 (No. 3), pp. 409-14, (2005).
- 20- Xiaoli Wu *et al.*, "The prevalence of moderate-to-high posttraumatic growth: A systematic review and meta-analysis." *Journal of affective disorders*, Vol. 243pp. 408-15, (2019).
- 21- Bolanle Tinubu, Chidozie E Mbada, Adewale L Oyeyemi, and Ayodele A Fabunmi, "Work-related musculoskeletal disorders among nurses in Ibadan, South-west Nigeria: a cross-sectional survey." *BMC Musculoskeletal disorders*, Vol. 11 (No. 1), pp. 1-8, (2010).
- 22- Zi-Xuan Wang and You-Gu Hu, "High-intensity zone (HIZ) of lumbar intervertebral disc on T2-weighted magnetic resonance images: spatial distribution, and correlation of distribution with low back pain (LBP)." *European Spine Journal*, Vol. 21 (No. 7), pp. 1311-15, (2012).
- 23- Nikolai Bogduk, "Degenerative joint disease of the spine." *Radiologic Clinics of North America*, Vol. 50 (No. 4), pp. 613-28, (2012).
- 24- C Aprill and N Bogduk, "High-intensity zone: a diagnostic sign of painful lumbar disc on magnetic resonance imaging." *The British journal of radiology*, Vol. 65 (No. 773), pp. 361-69, (1992).
- 25- Baogan Peng, Shuxun Hou, Wenwen Wu, Chunli Zhang, and Yi Yang, "The pathogenesis and clinical significance of a high-intensity zone (HIZ) of lumbar intervertebral disc on MR imaging in the patient with discogenic low back pain." *European Spine Journal*, Vol. 15 (No. 5), pp. 583-87, (2006).
- 26- Chae-Hun Lim, Won-Hee Jee, Byung Chul Son, Dong-Hyun Kim, Kee-Yong Ha, and Chun-Kun Park, "Discogenic lumbar pain: association with MR imaging and CT

- discography." *European journal of radiology*, Vol. 54 (No. 3), pp. 431-37, (2005).
- 27- B Böhm, H Meinig, A Eckardt, S Schadmand-Fischer, and J Heine, "Correlation of degenerative intervertebral disk displacement using MRI with discography findings in patients with back pain." *Der Orthopade*, Vol. 34 (No. 11), pp. 1144-49, (2005).
- 28- Zi-Xuan Wang, You-Gu Hu, and Xiang-Min Chen, "Significance of the high-intensity zone located in the posterior annulus fibrosus for diagnosing discogenic low back pain." *Zhonghua Yi Xue Za Zhi*, Vol. 88 (No. 35), pp. 2478-81, (2008).
- 29- Huadong Wang *et al.*, "Correlation between high-intensity zone on MRI and discography in patients with low back pain." *Medicine*, Vol. 96 (No. 30), (2017).
- 30- Jian-yu Chen *et al.*, "Correlation between MR imaging and discography with provocative concordant pain in patients with low back pain." *The Clinical journal of pain*, Vol. 27 (No. 2), pp. 125-30, (2011).
- 31- Norbert Boos, Sabine Weissbach, Helmut Rohrbach, Christoph Weiler, Kevin F Spratt, and Andreas G Nerlich, "Classification of age-related changes in lumbar intervertebral discs: 2002 Volvo Award in basic science." *Spine*, Vol. 27 (No. 23), pp. 2631-44, (2002).
- 32- OL Osti, B Vernon-Roberts, R Moore, and RD Fraser, "Annular tears and disc degeneration in the lumbar spine. A post-mortem study of 135 discs." *The Journal of bone and joint surgery. British volume*, Vol. 74 (No. 5), pp. 678-82, (1992).
- 33- Maureen C Jensen, Michael N Brant-Zawadzki, Nancy Obuchowski, Michael T Modic, Dennis Malkasian, and Jeffrey S Ross, "Magnetic resonance imaging of the lumbar spine in people without back pain." *New England Journal of Medicine*, Vol. 331 (No. 2), pp. 69-73, (1994).
- 34- Tadeusz W Stadnik, Roland R Lee, Hugo L Coen, EC Neirynck, Therese S Buisseret, and MJ Osteaux, "Annular tears and disk herniation: prevalence and contrast enhancement on MR images in the absence of low back pain or sciatica." *Radiology*, Vol. 206 (No. 1), pp. 49-55, (1998).
- 35- Carl Hirsch and Fritz Schajowicz, "Studies on structural changes in the lumbar annulus fibrosus." *Acta Orthopaedica Scandinavica*, Vol. 22 (No. 1-4), pp. 184-231, (1952).
- 36- Timothy A Mirtz and Leon Greene, "Is obesity a risk factor for low back pain? An example of using the evidence to answer a clinical question." *Chiropractic & osteopathy*, Vol. 13 (No. 1), pp. 1-6, (2005).