

# A 3D Evaluation of Condyle Position of Skeletal Class I and III Patients: A Cone-Beam Computed Tomography Technique

Arman Saeedivahdat<sup>1</sup>, Tohid Babaei<sup>2\*</sup> , Nadereh Ariamanesh<sup>3</sup>, Hadi Monzavi<sup>4</sup>, Pouya Badri<sup>5</sup>, Ali Nokhbeh<sup>6</sup>

<sup>1</sup> Department of Oral and Maxillofacial Radiology, Faculty of Dentistry, Tabriz University of Medical Sciences, Tabriz, Iran

<sup>2</sup> Department of Periodontology, Faculty of Dentistry, Qazvin University of Medical Sciences, Qazvin, Iran

<sup>3</sup> Department of Restorative Dentistry, Faculty of Dentistry, Qazvin University of Medical Sciences, Qazvin, Iran

<sup>4</sup> Department of Prosthodontics, Faculty of Dentistry, Qazvin University of Medical Sciences, Qazvin, Iran

<sup>5</sup> Department of Orthodontics, Faculty of Dentistry, Qazvin University of Medical Sciences, Qazvin, Iran

<sup>6</sup> Department of Periodontology, Faculty of Dentistry, Qazvin University of Medical Sciences, Qazvin, Iran

\*Corresponding Author: Tohid Babaei  
Email: [toohid.babaeii@gmail.com](mailto:toohid.babaeii@gmail.com)

Received: 20 January 2023 / Accepted: 05 February 2023

## Abstract

**Purpose:** The present study aims to assess the differences in the condyle position for two skeletal classes using Cone-Beam Computed Tomography (CBCT) reconstructions for both sides and genders.

**Materials and Methods:** In this cross-sectional descriptive study, the CBCT images of 96 patients (20-60 years) were assessed. The participants were divided according to their Angle malocclusion classifications (Angle Classes I and III). The variables of the Anterior-Posterior position of the Condyle (APC), condylar angle in the axial plane (ACA), the Lateral Position of the Condyle in the axial plane (LPC), the Vertical Position of the Condyle (VPC), condylar angle in coronal dimension (CCA), and the difference of APC and VPC on both sides were measured. The measurements were analyzed using a one-way ANOVA and Tukey's post hoc test.

**Results:** The variables of APC, LPC, ACA, VDC, and the difference of the APC on both sides in the two skeletal classes were similar. The VPC and CCA were greater in Class III than in Class I. All variables representing the 3D position of the condyle were similar in men and women, as well as on the right and left in both skeletal classes, I and III.

**Conclusion:** Based on the 3D evaluation results of the condylar position, the skeletal classes III and I differed in the VPC and CCA; however, for the rest variables, there were no statistical differences.

**Keywords:** Temporomandibular Joint; Skeletal Class I; Skeletal Class III; Cone-Beam Computed Tomography.

## 1. Introduction

The mandibular bone is of unique importance among the bones of the craniofacial region; it participates in several activities, such as maintaining the airway, speaking, chewing, and giving a distinctive appearance to the face [1]. The disorders in the connection of the mandible and the base of the skull affect the vertical and sagittal discrepancies of the face [2]. The three-dimensional (3D) position of the condyle in the glenoid cavity has a direct effect on the anterior, posterior, and vertical position of the mandible, which affects the morphology of the face and is of particular importance in creating a growth pattern of the face [3]. It was found that there is a positive correlation between temporomandibular disorders and abnormal mandibular morphology [4-6].

In the majority of previous studies, panoramic and cephalometric radiographs have been used to assess the condyle's position. In these modalities, the measurement accuracy was reduced due to the superimposition of structures around the temporomandibular joint (TMJ) [7, 8]. In addition, they do not provide complete images of the TMJ joint because only two planes are observed in panoramic images [8]. Recent research has shown that cone-beam computed tomography (CBCT) modality is a proper imaging technique for evaluating bone fractures and the position of bones in the face [8, 9]. This technique is specifically designed for imaging the maxillofacial region to obtain 3D information with lower radiation exposure and cost than conventional computed tomography (CT) scans that are common in medical practices [10-13]. Easier access to this technology has given dentists the ability to obtain 3D images with higher spatial resolution, lower artifacts, and faster scanning times and use them for various procedures, from diagnosis to surgical guides [14, 15].

In the present study, the 3D position of the condyle was investigated using CBCT images for two skeletal classes, Class III (as the abnormal pattern) and Class I (as the normal pattern). Based on our search, a few studies have used 3D CBCT analysis to assess the positional and morphological characteristics of the TMJ in adults with skeletal Class III and Class I; however, the relevant assessment was not performed for the Iranian adult population in different vertical skeletal patterns.

## 2. Materials and Methods

### 2.1. Patients

In this cross-sectional descriptive study, CBCT (NewTom VGi, Verona, Italy) images of 48 patients (ranging 20-60 years, mean: 40 years) with skeletal Class I (24 men and 24 women) and 48 patients with skeletal Class III (24 men and 24 women) were selected. The images were obtained in the maxillofacial radiology department of Tabriz University of Medical Sciences in 2018.

The inclusion criteria were images of people in the age range of 20 to 60 years, no facial asymmetry, clear and high-quality images, and no surgical history of TMJ or the craniofacial region. The exclusion criteria were the existence of any pathological lesions or fractures, extensive anterior or posterior edentulousness, or severe attrition.

### 2.2. Three Dimensional CBCT

The following protocol was utilized for the TMJ images using CBCT: the field of view (FOV) was 16.0×13.0 cm<sup>2</sup>, and the exposure parameters were 120 kVp and 18 mAs.

NNT viewer software (version 8) was used to acquire sagittal, axial, and coronal of the TMJ images performed based on Alhammadi *et al.*'s [16, 17]. Cross-sectional sections with a thickness and distances of one millimeter and a section width of 150 mm perpendicular to each condyle's lateral and medial pole were prepared to produce modified sagittal views. The one showing the largest mediolateral dimension of the condyle was chosen from these sections.

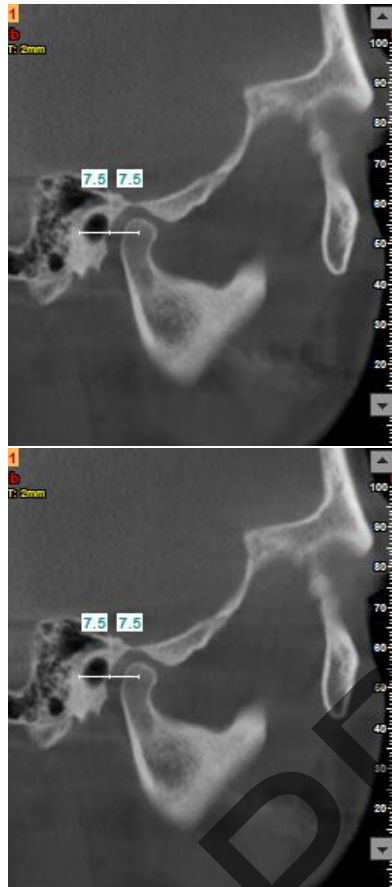The 3D images were oriented in such a way that the medial plane showed the skeletal midline, and the axial plane displayed the Frankfurt plane. Individuals with skeletal Class I and III were selected based on the ANB angle criteria (which measures the relative anteroposterior position between the maxilla and mandible) so that angles less than 0 degrees were classified as skeletal Class III and angles of 0 to 4 degrees were considered as Class I.

### 2.3. Measurement Parameters

Measurements acquired in the sagittal section (Figure 1):

Anterior-posterior position of the condyle (APC): the horizontal distance between the center point of the condyle and the outermost point on the posterior wall of the External Auditory Meatus (EAM).

The Vertical Position of the Condyle (VPC): the vertical distance between the center point of the condyle and the EAM.



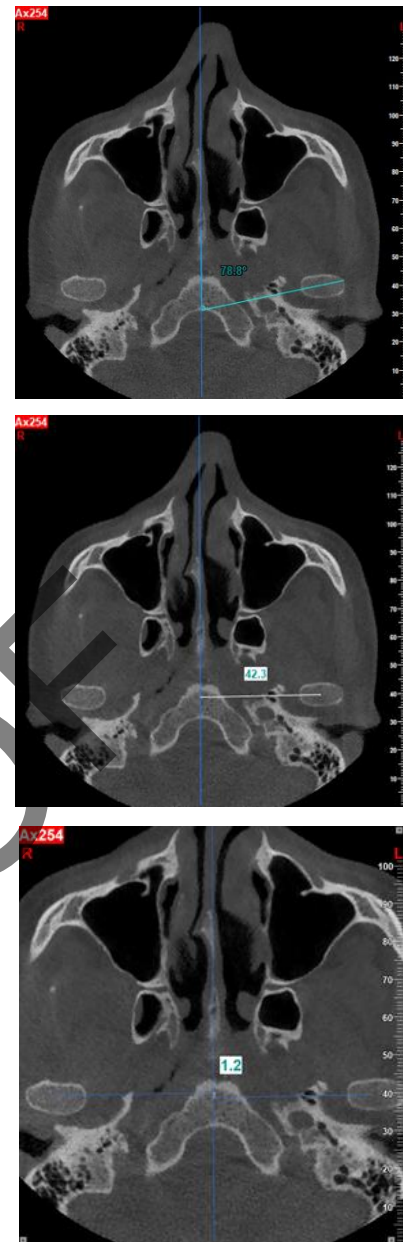
**Figure 1.** Measurements in sagittal sections; APC (Upper) and VPC (Bottom)

Measurements acquired in the axial section (Figure 2):

Axial Condylar Angle (ACA): the angle formed between the line connecting the center point of the condyle and the lateral pole of the condyle at its largest mediolaterally dimension with the patient's midsagittal plane.

The Lateral Position of the Condyle (LPC): the distance between the center point of the condyle and the midsagittal plane in millimeters.

Antero-posterior difference of condyle (APDC): the distance difference of the connecting line (between the center point of the condyle and the outer pole of the



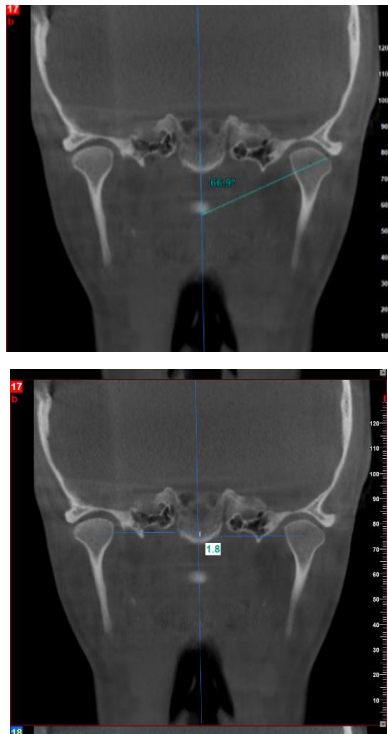
**Figure 2.** Measurements in axial sections; ACA (Upper), LPC (middle), APDC (Bottom)

left and right condyle), calculated along the line segment from these points on the sagittal plane.

Measurements acquired in the coronal plane (Figure 3):

Coronal Condylar Angle (CCA): the angle formed between the midsagittal plane and the line connecting the Laterosuperior Condyle (LSC) and the center of the condyle.

Vertical Difference of Condyles (VDC): the difference in vertical distance of the connecting line between the LSC and the center point of the left and right condyles, calculated along the line segment from these points on the sagittal plane.



**Figure 3.** Measurements in coronal sections; CCA (Upper), VDC (Bottom)

## 2.4. Analysis

Two observers repeated the measurements separately for both the left and right sides. To determine the reliability, they were repeated by the same person at two-week intervals. The results were reported as mean ± standard deviation. The measurements were performed using a one-way analysis of variance (ANOVA) test and Tukey’s post hoc test. All statistical analyses were performed using the SPSS software package, version 18 (IBM, USA). A P value less than 0.05 was considered a significant level.

## 3. Results

There was no significant difference between Class I and III in terms of APC, LPC, APDC, ACA, and VDC variations. The VPC in Class I was significantly less than in Class III ( $P = 0.027$ ). Also, the condylar angle in the CCA in Class I patients was considerably lower compared to Class III ( $P < 0.05$ ) (Table 1).

For both classes, there was no significant difference between males and females for all considered variables (Tables 2 and 3). In addition, all studied variables on the right and left of patients with Class I and III had not significantly different (Table 4).

**Table 1.** Comparison of the 3D position of the condyle in people with skeletal Class I and III

	Class III (48 patients)		Class I (48 patients)		P-value
	Mean	SD	Mean	SD	
ANB angle (degree)	-2.125	0.815	1.963	0.601	
APC (mm)	7.977	0.682	8.122	0.489	0.091
VPC (mm)	0.156	0.086	0.143	0.085	0.027
ACA (degree)	69.464	5.039	70.332	5.348	0.248
LPC (mm)	50.472	2.593	50.077	5.149	0.503
APDC (mm)	1.523	0.268	1.562	0.277	0.483
CCA (degree)	64.737	4.091	62.982	3.079	0.001
VDC (mm)	1.498	0.380	1.464	0.323	0.638

**Table 2.** Comparison of the 3D position of the condyle in women and men in patients with skeletal Class I

	Female (24 patients)		Male (24 patients)		P-value
	Mean	SD	Mean	SD	
APC (mm)	8.003	0.636	7.950	0.731	0.704
VPC (mm)	0.147	0.091	0.145	0.082	0.906
ACA (degree)	69.635	4.990	69.292	5.136	0.740
LPC (mm)	50.615	2.414	50.329	2.780	0.592
APDC (mm)	1.538	0.305	1.508	0.231	0.703
CCA (degree)	65.525	4.720	63.950	3.207	0.059
VDC (mm)	1.462	0.388	1.533	0.378	0.502

**Table 3.** Comparison of the 3D position of the condyle in men and women in people with skeletal Class III

	Women (24 patients)		Men (24 patients)		P-value
	Mean	SD	Mean	SD	
APC (mm)	8.003	0.636	7.950	0.731	0.704
VPC (mm)	0.147	0.091	0.145	0.082	0.906
ACA (degree)	69.635	4.990	69.292	5.136	0.740
LPC (mm)	50.615	2.414	50.329	2.780	0.592
APDC (mm)	1.538	0.305	1.508	0.231	0.703
CCA (degree)	65.525	4.720	63.950	3.207	0.059
VDC (mm)	1.462	0.388	1.533	0.378	0.520

**Table 4.** Comparison of the 3D position of the condyle on the left and right of the mandible in people with skeletal Class I and Class III

		Class III		Class I	
		Mean	SD	Mean	SD
APC (mm)	Right	7.955	0.694	8.123	0.505
	Left	7.998	0.677	8.121	0.478
	P-value		0.760		0.931
VPC (mm)	Right	0.146	0.088	0.140	0.093
	Left	0.146	0.086	0.145	0.077
	P-value		0.981		0.975
ACA (degree)	Right	69.544	4.796	70.360	5.471
	Left	69.383	5.321	70.304	5.279
	P-value		0.730		0.880
LPC (mm)	Right	50.457	1.638	50.636	1.466
	Left	50.487	3.303	49.518	7.128
	P-value		0.955		0.290
CCA (degree)	Right	64.329	3.533	63.306	2.947
	Left	65.146	4.583	62.658	3.203
	P-value		0.330		0.305

## 4. Discussion

We assessed the positions of the right and left condyles between class I and class III patients using CBCT panoramic reconstructions.

In the present study, most of the assessed variables (APC, ACA, LLPC, APDC, VDC) were similar in the two skeletal classes; however, the VPC and CCA were higher in Class III patients than in Class I.

In accordance with our findings, Mishra *et al.* [18] evaluated the three-dimensional position of the condyle in growing patients with skeletal Class I and III using CBCT images. They also reported that all the variables (CCA, APC, VPC, ACA, LPC, APDC, VDC) were similar in the two skeletal classes, except for CCA and VPC variables. The levels of APC, ACA, and LPC in the two skeletal classes were similar to the present study. The difference in APDC was similar in Class I and Class III, which is in

agreement with our study. We measured these variables on adult patients; however, Mishra *et al.*'s assessments were performed on young and growing patients (7-14 years) [18]. In our study, the values of CCA in Class I patients were significantly lower than in class III patients ( $P < 0.05$ ), which were in contrast to the results reported by Mishra *et al.* These differences could be related to the differences in the studied patients. Alhammedi *et al.* [16] showed that the three skeletal classes had a significant difference in the vertical position of the condyle, and patients in class III had the highest VPC. Class III patients also had the lowest APC, the least internal joint spaces, the largest width of the fossa, and the largest APDC. In our study, Class III patients had higher VPC, and lower APC, which are consistent with Alhammedi *et al.*'s study. However, in contrast to Alhammedi *et al.*, we found statistically similar APDC values between class I and III patients. In a study by Arieta *et al.* [19], the spatial position of the condyle in individuals with skeletal I, II, and III classes was measured using CBCT images. They concluded that in the class III patients, the

condyles were placed in more superior and anterior positions compared to class I patients.

Al hadad *et al.* [20] evaluated the position and morphology of TMJ in 80 Chinese adults with skeletal Class II with mandibular retrognathism in different vertical skeletal patterns using 3D images obtained from CBCT. They classified the studied patients into four identical-size groups according to the mandibular angle and facial height ratio, including hypodivergent, normodivergent, and hyperdivergent groups, as well as a control group. They reported significant differences in the hyperdivergent and hypodivergent groups compared with the normal group in the vertical and anteroposterior mandibular fossa position, vertical condylar inclination, and condylar width and length. They noted that these differences could be considered during temporomandibular disorders (TMDs) diagnosis and orthodontic treatment. The inconsistency in some parameters between our study and the findings of previous studies could also be related to orthodontic

treatments and diagnosis. However, this issue cannot reduce the value of the current research or previous studies' findings. Because to better understand and know the parameters of the condyle position in different patients, it is necessary to summarize the results of all studies.

The results of our study showed that there were no significant differences between men and women in evaluated parameters for the patients in both skeletal classes I and III. Furthermore, there is no study comparing the positions of the right and left condyles between women and men. Akbulut *et al.* showed that male patients in both Class I and III groups had a higher distance between the condylar and fossa on the right [21]. In our investigation, there was no significant difference in the 3D condyle positional parameters between the right and left in each of the skeletal classes I and III patient groups, which is consistent with Mishra *et al.* [18].

**Table 5.** The summarized results of previous studies assessing the condylar position using CBCT in patients with different skeletal classes

Study	Patients skeletal classes	Assessed parameters	Findings
Present study	Class I & III	APC, ACA, LPC, APDC, VDC, VPC, and CCA	The values of APC, ACA, LPC, and the difference of the APC on both sides in the two skeletal classes were similar. The VPC and CCA were greater in Class III than in Class I.
Mishra <i>et al.</i> , 2017	Class I & III	APC, ACA, LPC, APDC, VDC, VPC, and CCA	3D CBCT analysis shows no significant difference in the condylar position of skeletal Class I and Class III subjects except for CCA and VPC, which were higher in Class III patients.
Alhammadi <i>et al.</i> , 2016	Class I, II & III	*Condylar width, *condylar height, *anterior, superior, and medial joint spaces, *mandibular fossa width, *condylar position *and lots of anatomical bony points	Class II patients showed the lowest condylar width, the highest condylar height, and the highest anterior joint space. Class III patients exhibited the lowest anterior, superior, and medial joint spaces, the highest mandibular fossa width, and the highest anteroposterior condylar dimension. Class III had the most superior and Class II had the most inferior condylar position.
Arieta <i>et al.</i> , 2013	Class I, II & III	Several anatomical points and distances, such as upper distance, posterior distance, anterior distance, angle of eminence, and height of the eminence	There were several anatomical differences for the condylar position concerning the glenoid fossa for skeletal classes; however, these spatial differences may not be clinically relevant.
Akbulut <i>et al.</i> , 2019	Class I, II & III	Condyle-to-eminence distance, condyle-to-fossa distance, condyle-to-meatus distance, anatomical	The right condyle-to-eminence and right condyle-to-fossa distances were significantly different among the classes. Male patients seemed to have a greater condyle-to-fossa distance on the right side in both the Class I and III groups. The mean distance from the condyle to eminence, condyle to fossa, and condyle to meatus on the right side was the greatest in the Angle Class II group.
Al-hadad <i>et al.</i> , 2022	Class II	Condylar width, anterior joint space, posterior joint space, anterior, superior, and medial joint spaces condylar position, and lots of anatomical bony points designed by Alhammadi <i>et al.</i>	The hyperdivergent group showed the significantly highest condylar inclination with the midsagittal plane; anterior and superior positioning of the condyle; smallest anterior, superior, and medial joint spaces; and largest volumetric total joint space relative to the two other groups.

In Table 5, we summarized several similar studies that assessed condylar position among class I-III patients using CBCT imaging.

One limitation of our study was the wide age range of patients in the present study (20-60 years) due to the limited accessible samples. It must be noted that the position of the condyle can change during growth and aging, and it affects our results. Although for comparison, we tried to use identical groups regarding the patients' age, we suggested performing similar studies with patients in predefined and limited age ranges for the future. Furthermore, we did not consider patients with skeletal class II due to their small number in our database; therefore, these patients can also be subjected to similar research.

## 5. Conclusion

We investigated the positional parameters (APC, ACA, LPC, APDC, VDC, VPC, and CCA) of the condyles obtained from CBCT panoramic reconstruction. VPC and CCA variables were higher in class III than in class I patients. Other assessed parameters had not had significant differences between the two classes. Furthermore, all the parameters were similar in men and women, as well as on the right and left in both skeletal classes, I and III.

## Acknowledgments

This work was supported by the Faculty of Dentistry of Tabriz University of Medical Sciences.

## References

- 1- Denys H Goose and John Appleton, Human dentofacial growth. *Elsevier*, (2016).
- 2- Oana Almășan, Andreea Kui, Ioana Duncea, Avram Manea, and Smaranda Buduru, "Temporomandibular joint disk displacements in class II malocclusion and cervical spine alterations: systematic review and report of a hypodivergent case with MRI bone and soft tissue changes." *Life*, Vol. 12 (No. 6), p. 908, (2022).
- 3- Shruti Rathi, Rizwan Gilani, Ranjit Kamble, and Sakshi Bhandwalkar, "Temporomandibular Joint Disorder and Airway in Class II Malocclusion: A Review." *Cureus*, Vol. 14 (No. 10), (2022).
- 4- Risa Matsubara *et al.*, "Assessment of MRI findings and clinical symptoms in patients with temporomandibular joint disorders." *Dentomaxillofacial Radiology*, Vol. 47 (No. 4), p. 20170412, (2018).
- 5- S Cömert Kiliç, N Kiliç, and MA Sümbüllü, "Temporomandibular joint osteoarthritis: cone beam computed tomography findings, clinical features, and correlations." *International journal of oral and maxillofacial surgery*, Vol. 44 (No. 10), pp. 1268-74, (2015).
- 6- James R Miller, Jeffrey A Burgess, and Cathy W Critchlow, "Association between mandibular retrognathia and TMJ disorders in adult females." *Journal of public health dentistry*, Vol. 64 (No. 3), pp. 157-63, (2004).
- 7- Oana Bida Honey *et al.*, "Accuracy of cone-beam computed tomography imaging of the temporomandibular joint: comparisons with panoramic radiology and linear tomography." *American journal of orthodontics and dentofacial orthopedics*, Vol. 132 (No. 4), pp. 429-38, (2007).
- 8- Michael L Hilgers, William C Scarfe, James P Scheetz, and Allan G Farman, "Accuracy of linear temporomandibular joint measurements with cone beam computed tomography and digital cephalometric radiography." *American journal of orthodontics and dentofacial orthopedics*, Vol. 128 (No. 6), pp. 803-11, (2005).
- 9- G Petrikowski, "Diagnostic imaging of the temporomandibular joint." *Oral Health*, Vol. 95 (No. 6), p. 10, (2005).
- 10- Elluru Venkatesh and Snehal Venkatesh Elluru, "Cone beam computed tomography: basics and applications in dentistry." *Journal of istanbul University faculty of Dentistry*, Vol. 51 (No. 3 Suppl 1), p. S102, (2017).
- 11- Genevive L Machado, "CBCT imaging—A boon to orthodontics." *The Saudi dental journal*, Vol. 27 (No. 1), pp. 12-21, (2015).
- 12- John B Ludlow, "Dose and risk in dental diagnostic imaging: with emphasis on dosimetry of CBCT." *Imaging Science in Dentistry*, Vol. 39 (No. 4), pp. 175-84, (2009).
- 13- John B Ludlow and Marija Ivanovic, "Comparative dosimetry of dental CBCT devices and 64-slice CT for oral and maxillofacial radiology." *Oral Surgery, Oral Medicine, Oral Pathology, Oral Radiology, and Endodontology*, Vol. 106 (No. 1), pp. 106-14, (2008).
- 14- Holly L Stewart, Jeffery H Siewerdsen, Brad B Nelson, and Christopher E Kawcak, "Use of cone-beam computed tomography for advanced imaging of the equine patient." *Equine veterinary journal*, Vol. 53 (No. 5), pp. 872-85, (2021).
- 15- John W Ballrick, J Martin Palomo, Edward Ruch, B Douglas Amberman, and Mark G Hans, "Image distortion and spatial resolution of a commercially available cone-

- beam computed tomography machine." *American journal of orthodontics and dentofacial orthopedics*, Vol. 134 (No. 4), pp. 573-82, (2008).
- 16- Maged Sultan Alhammadi, Mona Salah Fayed, and Amr Labib, "Three-dimensional assessment of temporomandibular joints in skeletal Class I, Class II, and Class III malocclusions: cone beam computed tomography analysis." *Journal of the World Federation of Orthodontists*, Vol. 5 (No. 3), pp. 80-86, (2016).
- 17- Abbas Ahmed Abdulqader, Liling Ren, Maged Alhammadi, Zainab Abdulkader Abdu, and Abdo Ahmed Saleh Mohamed, "Three-dimensional analysis of temporomandibular joint in Chinese adults with normal occlusion and harmonious skeleton." *Oral Radiology*, Vol. 36pp. 371-82, (2020).
- 18- Rajiv Kumar Mishra, Om Prakash Kharbanda, and Rajiv Balachandran, "3D CBCT evaluation of condyle position in skeletal class I & class III growing subjects." *Orthodontic Journal of Nepal*, Vol. 7 (No. 2), pp. 9-14, (2017).
- 19- Jessica M Arieta-Miranda, Manuel Silva-Valencia, Carlos Flores-Mir, Ney A Paredes-Sampen, and Luis E Arriola-Guillen, "Spatial analysis of condyle position according to sagittal skeletal relationship, assessed by cone beam computed tomography." *Progress in orthodontics*, Vol. 14 (No. 1), pp. 1-9, (2013).
- 20- Saba Ahmed Al-Hadad, Enas Senan ALyafrose, Abbas Ahmed Abdulqader, Waseem Saleh Al-Gumaei, Rana AAM Al-Mohana, and Liling Ren, "Comprehensive three-dimensional positional and morphological assessment of the temporomandibular joint in skeletal Class II patients with mandibular retrognathism in different vertical skeletal patterns." *BMC oral health*, Vol. 22 (No. 1), pp. 1-12, (2022).
- 21- Aslihan Akbulut and Delal Dara Kılınc, "Evaluation of condyle position in patients with Angle Class I, II, and III malocclusion using cone-beam computed tomography panoramic reconstructions." *Oral Radiology*, Vol. 35pp. 43-50, (2019).