

ORIGINAL ARTICLE

Investigating the Macular Vasculature Using Optical Coherence Tomography Angiography in the Early Period Following Pan-Retinal Photocoagulation in Diabetic Retinopathy

Mohammadreza Ansari Astaneh, Nasim Shahsavan Gharbi* , Mojtaba Abrishami, Elham Bakhtiari, Mehrdad Motamed Shariati

Eye Research Center, Khatam Al-Anbia Eye Hospital, Mashhad University of Medical Sciences, Mashhad, Iran

*Corresponding Author: Nasim Shahsavan Gharbi
Email: Nasim.shahsavan@gmail.com

Received: 19 July 2023 / Accepted: 02 September 2023

Abstract

Purpose: This study used Optical Coherence Tomography Angiography (OCTA) to examine the progression of the macular flow profile over the course of a month following Pan-Retinal Photocoagulation (PRP).

Materials and Methods: A total of Thirteen individuals in the earliest stages of Proliferative Diabetic Retinopathy (PDR) were included in this follow-up investigation. This study has excluded patients who have had prior therapy for Diabetic Retinopathy (DR) or any other retinal disease. Before and after PRP treatment, all participants had a comprehensive eye exam and had a macular optical coherence tomography angiography (AngioVue RTVue XR Avanti, Optovue, Fremont, CA, USA, software version: 2018,0,0,18) performed using a 6-by-6-millimeter scan size. Superficial and deep capillary plexus were analyzed.

Results: 13 patients, 6 male (46%) and 7 female (54%), with PDR, participated in this study. The mean± Sd of the patient's age was 55.25±9.28 years. Foveal Avascular Zone (FAZ), Deep Vessel Density (DVD), macular Superficial Vessel Density (SVD), and area alterations in PDR patients before and after PRP were not statistically significant, according to this study.

Conclusion: Although a reduction in SFVD, DFVD, and FAZ area in the 1st month following PRP was shown. PRP in patients with early PDR stage of diabetic retinopathy did not have a significant effect on the macular vasculature during the first month of treatment.

Keywords: Macula; Blood Flow; Pan-Retinal Photocoagulation; Angiography of Optical Coherence Tomography.

1. Introduction

Retinal microvascular damage is the underlying cause of diabetic retinopathy, which manifests clinically as a constellation of abnormalities, including vascular leakage, hard exudate buildup, microaneurysms, hemorrhages, and neovascularization [1]. The existence of neovascular tissues characterizes the advanced stage of the illness known as Proliferative Diabetic Retinopathy (PDR). Vascular Endothelial Growth Factor (VEGF), a growth factor generated from ischemic tissues, plays a key role in the formation of PDR [2]. The current gold standard for treating PDR is pan-retinal photocoagulation (PRP). The main effects of PRP that cause decreased VEGF concentrations are increased oxygen tension and decreased demand [3]. Ischemia can occur when VEGF levels drop, as it helps endothelial cells stay alive [4, 5].

The examination of fundus microvasculature without the injection of dye is quick, easy, and affordable with Optical Coherence Tomography Angiography (OCTA) [6].

This study aims to investigate changes in macular vasculature in PDR patients before and in different periods after PRP (one hour, one week, and one month) using OCTA.

2. Materials and Methods

The purpose of this study, which was undertaken at the "Mashhad University of Medical Sciences" using a convenience sample technique, was to assess the impact of PRP on retinal microcirculation in patients with PDR. Participants had early-stage PDR and had not previously received intravitreal anti-VEGF injections or PRP. The exclusion criteria included a history of uveitis, extensive neovascularization with high-risk PDR, evidence of vitreomacular traction, uncontrolled glaucoma, fibrovascular traction, center-involving diabetic macular edema (CI-DME), or previously received treatment for diabetic retinopathy.

The study was performed under the auspices of the Declaration of Helsinki and approved by the Mashhad University of Medical Sciences ethical committee (approval number: "IR.MUMS.MEDICAL.REC.1399/554"). Informed consent was obtained from the patients.

All study participants underwent a series of ophthalmic examinations, which included the measurement of Best-Corrected Distance Visual Acuity (BCVA) using a thumbing E chart, slit-lamp biomicroscopy, Goldmann applanation tonometry, a comprehensive dilated fundus examination with a +90D condensing lens, and macular OCTA (AngioVue RTVue XR Avanti, Optovue, Fremont, CA, USA, software version: 2018,0,0,18) with a scan size of 6 * 6 mm. PRP was performed in one session with a spot number of 1200-1500 and a size of 300 and with an average effect at a distance of two disc diameters from the nasal part and outside the arcade by a surgeon with the "pattern ellex" device and green light at the laser center of "Khatam Al Anbia Hospital" in Mashhad. If the patients needed treatment with intravitreal injection of Avastin or Added PRP or MPC (macular photocoagulation) or any other surgical procedure during the research process, they were excluded from the study.

The analysis was centered on the examination of both the superficial and deep capillary plexus. The quantification of foveal Vessel Density (VD) pertains to the measurement of blood vessel density in the superficial capillary plexus, specifically spanning from the internal limiting membrane to the inner plexiform layer. The evaluation was performed within a circular region measuring 1mm in diameter, positioned at the central point of the fovea. The concept of "parafoveal vascular density" (VD) pertains to the circular region that encompasses the area between the foveal region and a 2.5 × 2.5 mm region centered on the foveal center. The term "perifoveal vascular density" pertains to the spatial area situated between the external demarcation of the parafovea and a circular region measuring 3.5 × 3.5 mm in diameter, which is positioned at the center of the fovea. The photographs were taken without the use of pharmacologic mydriasis and after a period of rest lasting 3-5 minutes. The measurements were undertaken within the temporal span of 8:00 a.m. to 12:00 p.m. Images with a quality index below 6/10 were excluded from the analysis, and the imaging process was subsequently repeated. The present study involved the examination and evaluation of the macular vascular profile, which involved the assessment of several parameters. These parameters included the measurement of the density of superficial and deep vessels in the foveal region, as well as the

measurement of the density of superficial and deep vessels in the parafoveal region. Furthermore, an investigation was conducted on the FAZ area. Several examinations and imaging procedures were performed before and at different time points after the administration of Platelet-Rich Plasma (PRP). The intervals encompassed durations of one hour, one week, and one month.

Statistical analysis was conducted using version 22 of the Statistical Package for Social Sciences (SPSS) software, developed by IBM Corporation in Chicago, IL. The data distribution was examined using the Shapiro-Wilk test. Descriptive statistical methods, such as central indices and indices of dispersion, were utilized to delineate the characteristics of the subjects. General linear models, specifically repeated measure analysis of variance (ANOVA), were employed to examine any statistically significant alterations in macular vascular parameters over the duration of the study.

3. Results and Discussion

Regarding the previously mentioned criteria, 13 patients, 6 male (46%) and 7 female (54%), with PDR, participated in this study. In cases when both of a patient's eyes met the study's inclusion criteria, a single eye was selected at random for participation. The mean age of the patients was 55.25 ± 9.28 years.

3.1. Foveal Flow Profile

Table 1 presents a summary of the descriptive statistics pertaining to the values of superficial and deep foveal vessel density (SFVD and DFVD) as well as the area of the FAZ before and after pan-retinal photocoagulation (PRP) at three different time intervals: one hour, one week, and one month.

The Shapiro-Wilk test indicated that foveal vascular parameters followed a normal distribution, thus we employed the repeated-measures analysis of variance (ANOVA) to determine whether or not the observed variations in foveal blood flow were statistically significant. As depicted in Figures 1, 2, and 3, the

Table 1. Descriptive statistics of foveal flow profile before and after Pan retinal photocoagulation (PRP)

Foveal flow profile (percent)	N	Mean	Standard deviation (Sd)	P-Value (Repeated measure ANOVA)	Pairwise Baseline Vs 1 month
SFVD					
before PRP	13	14.74	5.48	0.144	0.091
one hour following PRP	13	13.75	6.50		
one week following PRP	13	16.59	5.68		
one month following PRP	13	12.09	7.27	0.622	0.95
DFVD					
before PRP	13	30.92	9.99		
one hour following PRP	13	29.74	7.78	0.561	0.95
one week following PRP	13	30.77	8.53		
one month following PRP	13	28.56	7.91		
FAZ area					
before PRP	13	0.34	0.11	0.561	0.95
one hour following PRP	13	0.40	0.18		
one week following PRP	13	0.33	0.10		
one month following PRP	13	0.32	0.13		

SFVD: Superficial foveal vessel density, DFVD: Deep foveal vessel density, FAZ: Foveal avascular zone

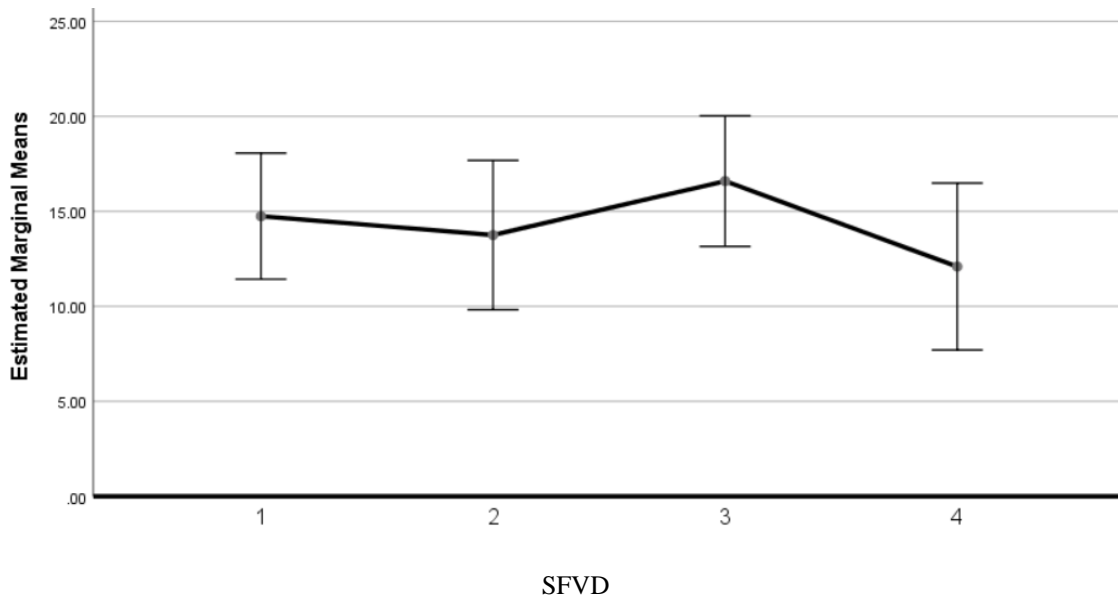


Figure 1. Estimated marginal means of Superficial Foveal Vessel Density (SFVD). 1: Measurement before Pan Retinal Photocoagulation (PRP). 2: Measurement one hour following PRP. 3: Measurement one week following PRP. 4: Measurement one month following PRP

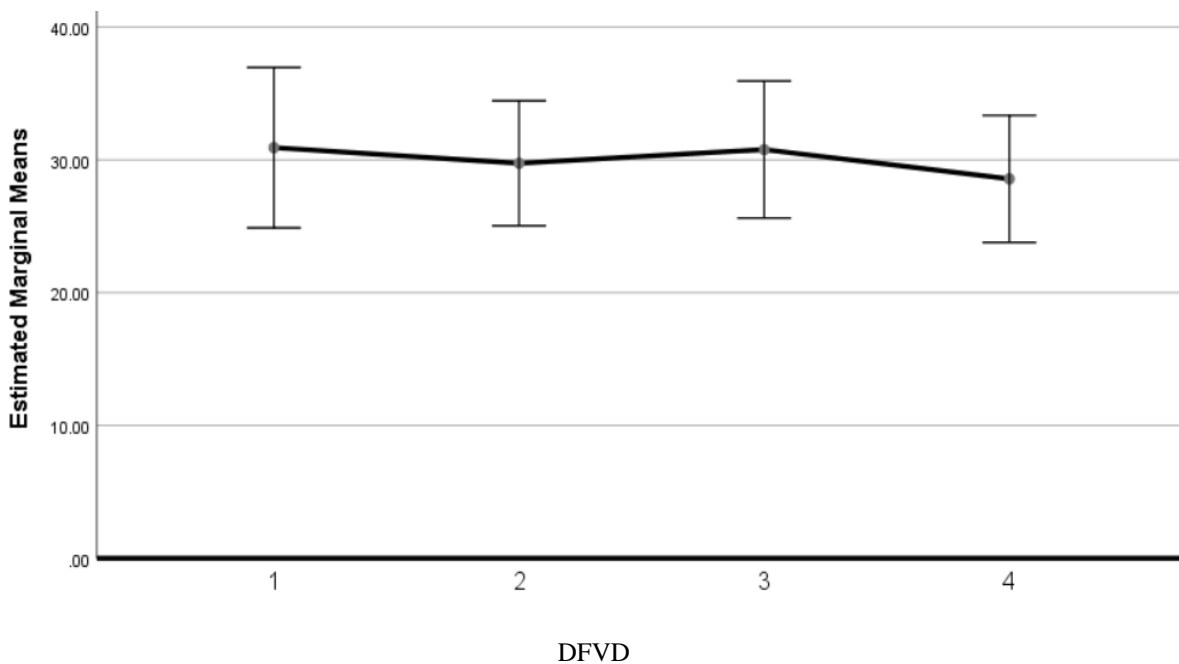


Figure 2. Estimated marginal means of Deep foveal vessel density (DFVD). 1: Measurement before Pan retinal photocoagulation (PRP). 2: Measurement one hour following PRP. 3: Measurement one week following PRP. 4: Measurement one month following PRP

alterations in SFVD, DFVD, and FAZ areas among patients with PDR before and during various post-pan-retinal photocoagulation (PRP) periods did not exhibit statistically significant differences.

3.2. Parafoveal Flow Profile

Table 2 presents a summary of the descriptive statistics for superficial and deep parafoveal vessel density (SPFVD and DPFVD) values both before and after Pan-Retinal Photocoagulation (PRP) at three different time points: one hour, one week, and one month.

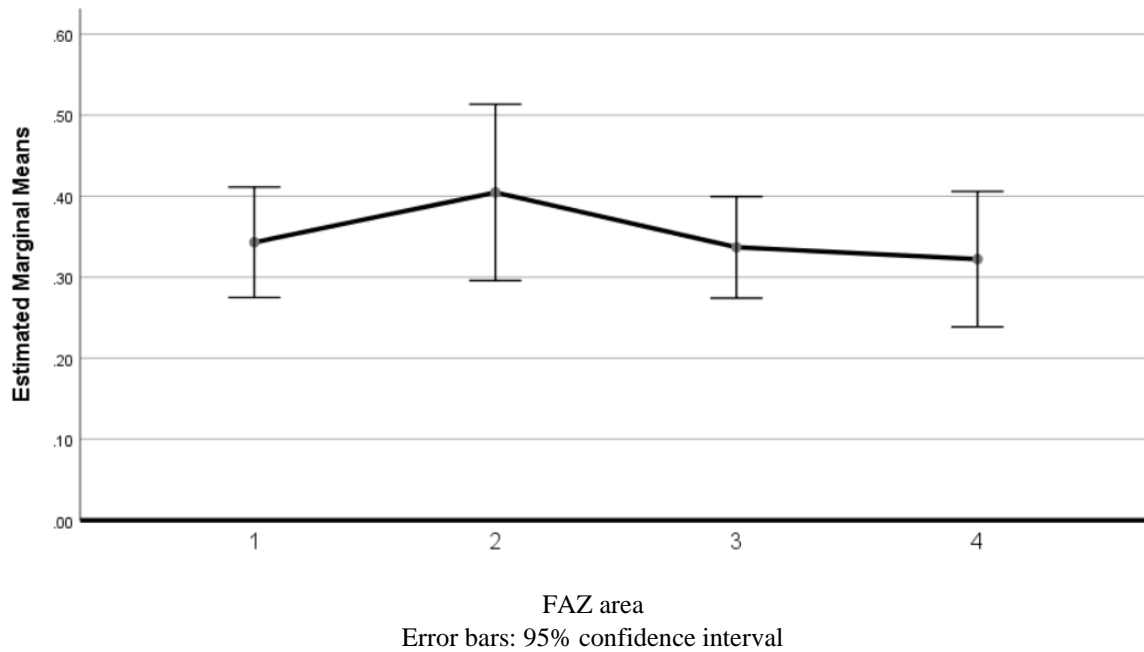


Figure 3. Estimated marginal means of FAZ area. 1: Measurement before Pan retinal photocoagulation (PRP). 2: Measurement one hour following PRP. 3: Measurement one week following PRP. 4: Measurement one month following PRP

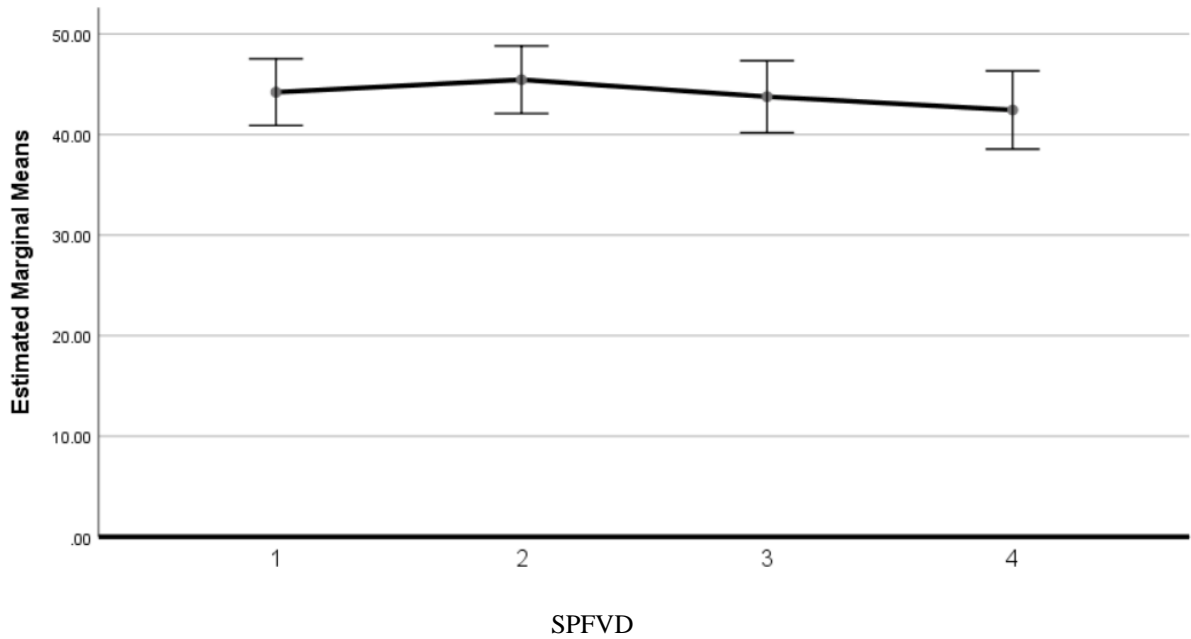
Table 2. Descriptive statistics of parafoveal flow profile before and after Pan retinal photocoagulation (PRP)

Parafoveal flow profile (percent)	N	Mean	Standard deviation (Sd)	P-Value (Repeated measure ANOVA)	Pairwise Baseline Vs 1 month
SPFVD					
before PRP	13	44.21	5.48	0.368	1.00
one hour following PRP	13	45.45	5.56		
one week following PRP	13	43.76	5.92		
one month following PRP	13	42.44	6.43		
DPFVD					
before PRP	13	47.48	6.29	0.106	0.95
one hour following PRP	13	47.16	6.41		
one week following PRP	13	49.40	5.55		
one month following PRP	13	47.60	7.66		

SPFVD: Superficial parafoveal vessel density, DPFVD: Deep parafoveal vessel density

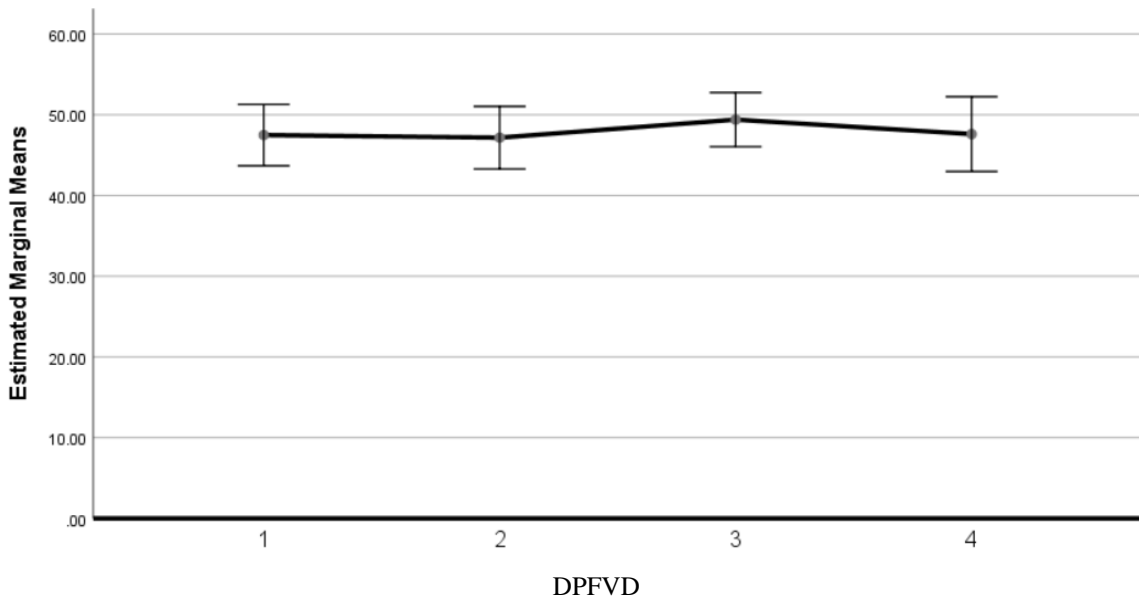
We used general linear models, i.e., repeated measure ANOVA, to evaluate the changes in the parafoveal flow profile before and after PRP. As we showed in [Figures 4 and 5](#), respectively, changes in SPFVD and DPFVD in PDR patients before and in

different periods after PRP were not statistically significant.



Error bars: 95% confidence interval

Figure 4. Estimated marginal means of Superficial parafoveal vessel density (SPFVD). 1: Measurement before Pan retinal photocoagulation (PRP). 2: Measurement one hour following PRP. 3: Measurement one week following PRP. 4: Measurement one month following PRP



Error bars: 95% confidence interval

Figure 5. Estimated marginal means of Deep parafoveal vessel density (DPFVD). 1: Measurement before Pan retinal photocoagulation (PRP). 2: Measurement one hour following PRP. 3: Measurement one week following PRP. 4: Measurement one month following PRP

3.3. Perifoveal Flow Profile

Table 3 presents a summary of the descriptive statistics for the values of superficial and deep perifoveal vessel density (SPeFVD and DPeFVD) before and after pan-retinal photocoagulation (PRP) at three different time points: one hour, one week, and one month.

We used general linear models, i.e., repeated measure ANOVA, to evaluate the changes in the parafoveal flow profile before and after PRP. As we showed in Figures 6 and 7, respectively, changes in SPFVD and DPFVD in PDR patients before and in different periods after PRP were not statistically significant.

Table 3. Descriptive statistics of perifoveal flow profile before and after Pan retinal photocoagulation (PRP)

Perifoveal flow profile (percent)	N	Mean	Standard deviation(Sd)	P-Value (Repeated measure ANOVA)	Pairwise Baseline Vs 1 month
SPeFVD					
before PRP	13	42.23	13.46	0.331	0.931
one hour following PRP	13	46.43	4.70		
one week following PRP	13	42.80	13.49		
one month following PRP	13	35.26	20.58		
DPeFVD					
before PRP	13	40.37	14.10	0.740	0.95
One hour following PRP	13	43.12	9.54		
one week following PRP	13	42.52	14.34		
one month following PRP	13	41.17	14.35		

SPeFVD: Superficial perifoveal vessel density, DPeFVD: Deep perifoveal vessel density

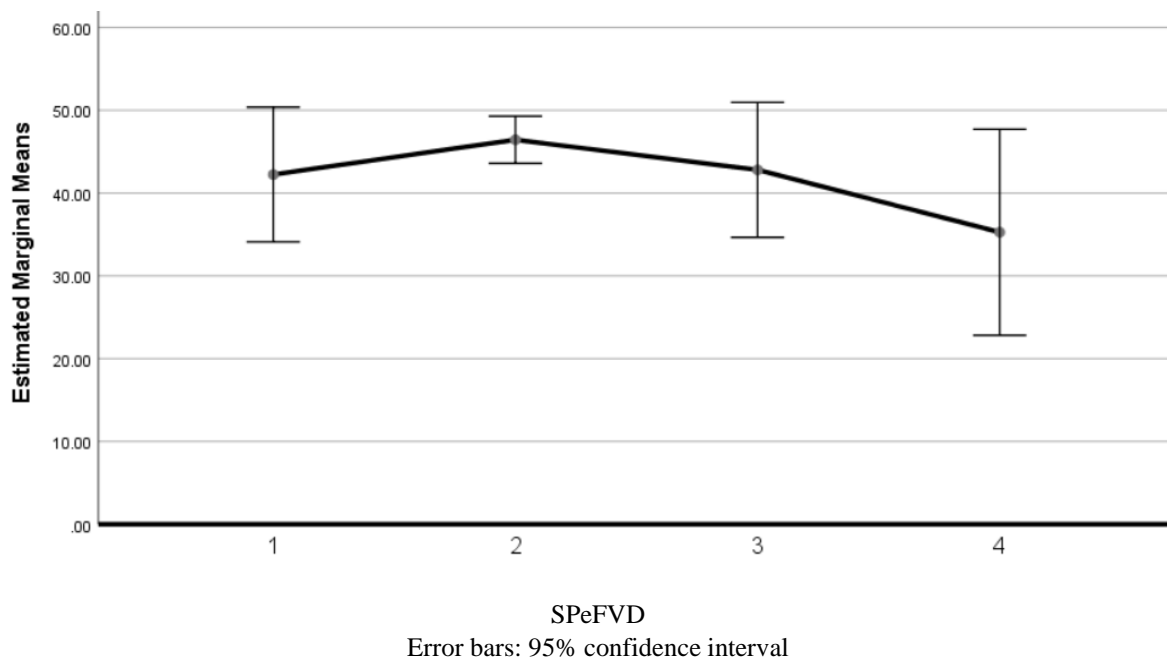


Figure 6. Estimated marginal means of Superficial perifoveal vessel density (SPeFVD). 1: Measurement before Pan retinal photocoagulation (PRP). 2: Measurement one hour following PRP. 3: Measurement one week following PRP. 4: Measurement one month following PRP

4. Conclusion

At present, the primary therapeutic intervention employed for individuals with diabetes in the PDR stage

is pan-retinal photocoagulation (PRP) [7]. The implementation of laser photocoagulation results in the decrease of VEGF levels through the reduction of tissue oxygen and nutrient requirements [8]. The OCTA technique facilitates the assessment of hemodynamic

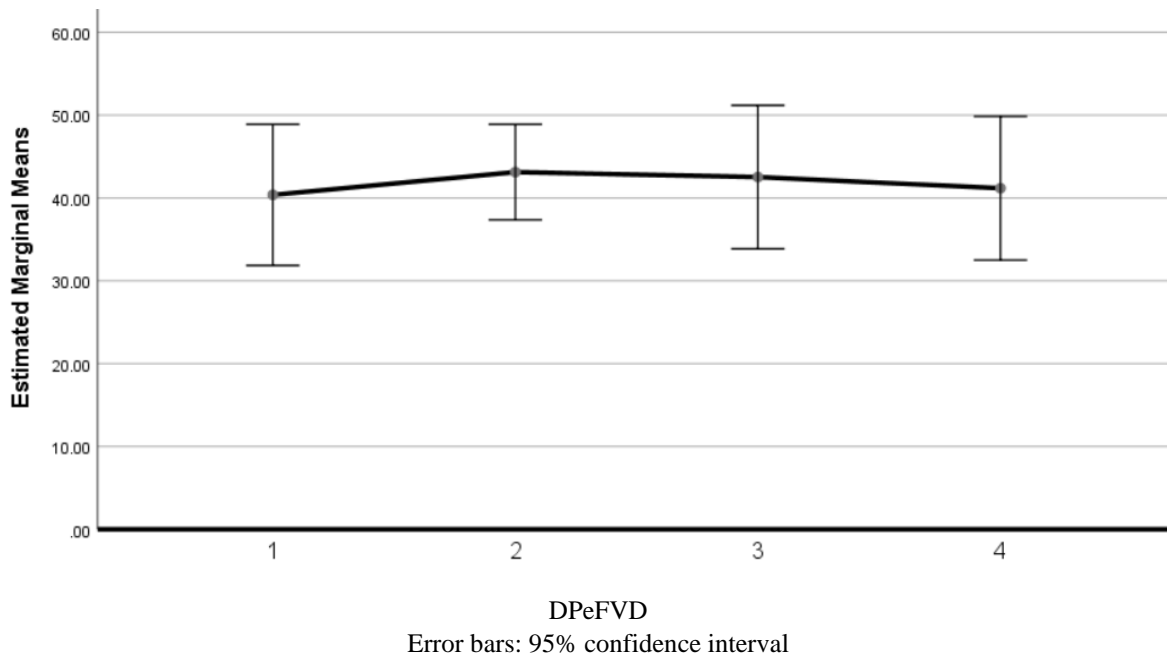


Figure 7. Estimated marginal means of Deep perifoveal vessel density (DPeFVD). 1: Measurement before Pan retinal photocoagulation (PRP). 2: Measurement one hour following PRP. 3: Measurement one week following PRP. 4: Measurement one month following PRP

alterations in the macular flow profile subsequent to Pan-retinal Photocoagulation (PRP). Several studies have demonstrated a detrimental impact of decreased VEGF levels on blood flow in the macula. One potential explanation for this observation pertains to the function of VEGF as an essential growth factor crucial for the viability of vascular endothelial cells. While certain studies have demonstrated a positive enhancement in macular blood flow subsequent to PRP treatment, contrasting findings have indicated no substantial alteration in this regard [9-11].

The objective of this study was to assess any alterations in the macular flow profile within the initial month following pan-retinal photocoagulation (PRP). The findings of our study revealed a discernible pattern of fluctuation in the flow parameters of the foveal, parafoveal, and perifoveal regions. Although there was a decrease in the size of subfoveal vascular density (SFVD), deep foveal vascular density (DFVD), and FAZ area within the initial month after pan-retinal photocoagulation (PRP), this observed alteration did not reach statistical significance. Based on the findings of this investigation, it can be inferred that the magnitude of blood flow variations within the deep vascular plexus across all macular regions is comparatively lower than that observed within the superficial vascular network. Nevertheless, all of these

alterations lacked significance. One plausible hypothesis to account for variations in blood flow during the initial stage (within the first month) subsequent to platelet-rich plasma (PRP) treatment is the dynamic alteration in cytokine levels, such as VEGF, interleukin-6, intercellular adhesion molecule-1, and monocyte chemoattractant protein-1 [12-14]. The thermal impact of photocoagulation on retinal pigment epithelium (RPE) cells induces the secretion of proangiogenic and inflammatory molecules during the initial phase. However, as time progresses, the reduction in tissue requirements results in a decline in the synthesis of proangiogenic factors [15].

The findings of our study were consistent with those of Lorusso *et al.* (2019), who conducted an assessment of OCTA parameters one month after PRP utilizing a frequency-doubled Nd: YAG pattern scan laser. The researchers reached the conclusion that laser treatment does not have a significant impact on the macular flow profile within a one-month timeframe [16].

Faghihi *et al.* conducted an additional study wherein they assessed alterations in macular vascular density. The study demonstrated that there was a noticeable rise in vascular density in the fovea and parafovea after a duration of one month. However, it is important to note that this observed increase did not

reach statistical significance [17]. This discovery is incongruent with our findings. In our study, a pairwise comparison was conducted to examine the macular flow profile. The results revealed a decreasing pattern, although it did not reach statistical significance.

In their study conducted in 2022, Abdelkarim *et al.* examined the alterations in OCTA parameters subsequent to pan-retinal photocoagulation (PRP) treatment in individuals diagnosed with high-risk PDR. The researchers observed a statistically significant enhancement in both superficial and DVD within the fovea and parafovea regions during the 1-month and 6-month follow-up intervals [18]. One notable distinction between the present study and our own research pertains to the varying degrees of severity of diabetic retinopathy observed among the participants. The potential impact of platelet-rich plasma (PRP) on the vasculature of the macula may vary depending on the stage of diabetic retinopathy. Moreover, it has been observed that individuals diagnosed with high-risk PDR stages exhibit a more unfavorable macular perfusion profile in comparison to those in the early PDR or severe non-proliferative diabetic retinopathy (NPDR) stages [19].

Diabetic microangiopathy is responsible for the occurrence of capillary dropout, resulting in the enlargement and irregularity of the FAZ. The FAZ area has been identified as a significant biomarker for both the severity and progression of diseases [20]. Previous studies have examined the impact of platelet-rich plasma (PRP) on the FAZ area. Evidence suggests that reducing the concentration of inflammatory and proangiogenic cytokines has a positive impact on the perfusion profile in the fovea [16, 21]. Our study demonstrated that one month after undergoing PRP treatment, there was a reduction in the size of the FAZ and an improvement in macular perfusion. Nevertheless, the results of our study did not demonstrate statistical significance.

In relation to the constraints of this study, it is suggested that future research endeavors should consider enhancing the validity of the findings by employing a study design that incorporates a more substantial sample size. The study excluded patients with a history of diabetic macular edema (DME), active DME, and a history of treatment for DME due to the detrimental effects of DME on the quality and interpretation of OCTA imaging [22]. Given the elevated incidence of Diabetic Macular Edema (DME) in individuals diagnosed with PDR, enlarging the sample size may

present certain difficulties. Additionally, the objective of this study was to assess the immediate alterations in the macular flow profile subsequent to PDR. A more extensive period of observation could provide a more comprehensive understanding of the enduring impacts of photocoagulation on the density of macular vessels. In addition, it is imperative to conduct subjective evaluations such as visual acuity, contrast sensitivity, color vision, and central 10-degree visual field assessments in order to comprehensively assess the impact of macular flow changes on the patient's visual function. Due to the uniformity of the study participants with regard to the severity of diabetic retinopathy, it was not feasible to conduct a comparative analysis of the impact of pan-retinal photocoagulation (PRP) on the macular flow profile across various stages of PDR.

Based on the findings of this study, it can be inferred that the macular flow profile exhibits a variable trajectory during the initial month subsequent to the event under investigation. Nevertheless, it is important to note that this observed pattern did not attain statistical significance.

References

- 1- Qingzheng Kang and Chunxue Yang, "Oxidative stress and diabetic retinopathy: Molecular mechanisms, pathogenetic role and therapeutic implications." *Redox biology*, Vol. 37p. 101799, (2020).
- 2- Samhitha Gudla, Divya Tenneti, Makrand Pande, and Srinivas M Tipparaju, "Diabetic retinopathy: pathogenesis, treatment, and complications." *Drug delivery for the retina and posterior segment disease*, pp. 83-94, (2018).
- 3- Wei Wang and Amy CY Lo, "Diabetic retinopathy: pathophysiology and treatments." *International journal of molecular sciences*, Vol. 19 (No. 6), p. 1816, (2018).
- 4- Ayman G Elnahry and Gehad A Elnahry, "Optical Coherence Tomography Angiography of Macular Perfusion Changes after Anti-VEGF Therapy for Diabetic Macular Edema: A Systematic Review." *Journal of Diabetes Research*, Vol. 2021 (No. 1), p. 6634637, (2021).
- 5- Irimi Chatziralli *et al.*, "Disentangling the association between retinal non-perfusion and anti-VEGF agents in diabetic retinopathy." *Eye*, Vol. 36 (No. 4), pp. 692-703, (2022).
- 6- Ines Lains *et al.*, "Retinal applications of swept source optical coherence tomography (OCT) and optical coherence tomography angiography (OCTA)." *Progress in retinal and eye research*, Vol. 84p. 100951, (2021).

- 7- Jae Wan Lim, Sang Joon Lee, Jae Yun Sung, Jin-soo Kim, and Ki Yup Nam, "Effect of prophylactic anti-VEGF injections on the prevention of recurrent vitreous hemorrhage in PDR patients after PRP." *Scientific Reports*, Vol. 12 (No. 1), p. 14484, (2022).
- 8- Yue Zhao and Rishi P Singh, "The role of anti-vascular endothelial growth factor (anti-VEGF) in the management of proliferative diabetic retinopathy." *Drugs in context*, Vol. 7(2018).
- 9- Beatrice Tombolini, Enrico Borrelli, Riccardo Sacconi, Francesco Bandello, and Giuseppe Querques, "Diabetic macular ischemia." *Acta Diabetologica*, Vol. 59 (No. 6), pp. 751-59, (2022).
- 10- Zi-Yi Zhu, Yong-An Meng, Bin Yan, and Jing Luo, "Effect of anti-VEGF treatment on nonperfusion areas in ischemic retinopathy." *International Journal of Ophthalmology*, Vol. 14 (No. 11), p. 1647, (2021).
- 11- Maryo Cenk Kohen, Sinan Tatlipinar, Alev Cumbul, and Ünal Uslu, "The effects of bevacizumab treatment in a rat model of retinal ischemia and perfusion injury." *Molecular vision*, Vol. 24p. 239, (2018).
- 12- Jin-woo Kwon and Jusang Oh, "Aqueous Humor Analyses in Patients with Diabetic Retinopathy Who Had Undergone Panretinal Photocoagulation." *Journal of Diabetes Research*, Vol. 2022 (No. 1), p. 1897344, (2022).
- 13- Zizhong Hu *et al.*, "Monitoring intraocular proangiogenic and profibrotic cytokines within 7 days after adjunctive anti-vascular endothelial growth factor therapy for proliferative diabetic retinopathy." *Acta Ophthalmologica*, Vol. 100 (No. 3), pp. e726-e36, (2022).
- 14- Aiko Ito, Yoshio Hirano, Miho Nozaki, Masayuki Ashikari, Kazuhiko Sugitani, and Yuichiro Ogura, "Short pulse laser induces less inflammatory cytokines in the murine retina after laser photocoagulation." *Ophthalmic research*, Vol. 53 (No. 2), pp. 65-73, (2015).
- 15- Glyn Chidlow, Malcolm Plunkett, Robert J Casson, and John PM Wood, "Glial cell and inflammatory responses to retinal laser treatment: comparison of a conventional photocoagulator and a novel, 3-nanosecond pulse laser." *Investigative ophthalmology & visual science*, Vol. 54 (No. 3), pp. 2319-32, (2013).
- 16- Massimo Lorusso *et al.*, "Panretinal photocoagulation does not change macular perfusion in eyes with proliferative diabetic retinopathy." *Ophthalmic Surgery, Lasers and Imaging Retina*, Vol. 50 (No. 3), pp. 174-78, (2019).
- 17- Hooshang Faghihi *et al.*, "Effect of panretinal photocoagulation on macular vasculature using optical coherence tomography angiography." *European Journal of Ophthalmology*, Vol. 31 (No. 4), pp. 1877-84, (2021).
- 18- Ahmed Shawkat Abdelhalim, Mohamed Farouk Sayed Othman Abdelkader, Mohamed Salah El-Din Mahmoud, and Asmaa Anwar Mohamed Mohamed, "Macular vessel density before and after panretinal photocoagulation in patients with proliferative diabetic retinopathy." *International journal of retina and vitreous*, Vol. 8 (No. 1), p. 21, (2022).
- 19- Dawei Yang *et al.*, "Macular capillary perfusion in Chinese patients with diabetic retinopathy obtained with optical coherence tomography angiography." *Ophthalmic Surgery, Lasers and Imaging Retina*, Vol. 50 (No. 4), pp. e88-e95, (2019).
- 20- Sunniva Kruse Johannesen, Julie Nilssen Viken, Anna Stage Vergmann, and Jakob Grauslund, "Optical coherence tomography angiography and microvascular changes in diabetic retinopathy: a systematic review." *Acta Ophthalmologica*, Vol. 97 (No. 1), pp. 7-14, (2019).
- 21- Mehmet Cem Sabaner, Mustafa Dogan, Muberra Akdogan, and Merve Şimşek, "Panretinal laser photocoagulation decreases large foveal avascular zone area in non-proliferative diabetic retinopathy: A prospective OCTA study." *Photodiagnosis and photodynamic therapy*, Vol. 34p. 102298, (2021).
- 22- Nicolas Cuenca *et al.*, "Interpretation of OCT and OCTA images from a histological approach: clinical and experimental implications." *Progress in retinal and eye research*, Vol. 77p. 100828, (2020).