


## ORIGINAL ARTICLE

# Clinical Evaluation of Tissue Healing around Gingival Former Following Dental Implant Uncovery with Two Different Diode Laser Wavelength

Maryam Abdolhazadeh<sup>1</sup>, Saiedeh Sadeghi<sup>2</sup>, Mohammad Ali Irani<sup>3</sup>, Amir Yari<sup>4</sup>, Kamal Attari<sup>5</sup>, Seyed Sasan Aryanezhad<sup>6</sup>, Salman Abolfazli-Karizi<sup>7\*</sup> 

<sup>1</sup> Department of Pediatric Dentistry, School of Dentistry, Tehran University of Medical Sciences, Tehran, Iran

<sup>2</sup> Department of Prosthodontics, School of Dentistry, University of Medical Sciences, Kerman, Iran

<sup>3</sup> Doctor of Dental Surgery, Dr Irani Clinic and Research Center, Tehran, Iran

<sup>4</sup> Oral and Maxillofacial Surgery Department, School of Dentistry, Kashan University of Medical Sciences, Kashan, Iran

<sup>5</sup> Endodontic Department, Faculty of Dentistry, Tabriz University of Medical Sciences, Tabriz, Iran

<sup>6</sup> Oral and Maxillofacial Radiologist, Private Practice, Tehran, Iran

<sup>7</sup> Department of Periodontics, School of Dental Medicine, Ahvaz Jundishapur University of Medical Sciences, Ahvaz, Iran

\*Corresponding Author: Salman Abolfazli-Karizi  
Email: [salmanabolfazli@yahoo.com](mailto:salmanabolfazli@yahoo.com)

Received: 03 September 2023 / Accepted: 20 September 2023

## Abstract

**Purpose:** It has been demonstrated that diode lasers can be an effective alternative in oral soft tissue surgeries. This study aimed to clinically evaluate the tissue healing around the gingival former of dental implants following the uncovery of areas with different diode laser wavelengths.

**Materials and Methods:** This study was conducted on 72 implants (in the Periodontology Department of the Faculty of Dentistry, Jundishapur University of Medical Sciences in Ahvaz, Iran, in 2015-2016) with two different diode laser wavelengths (940 and 810 nm). The samples were randomly assigned to two groups of 36 implants, including experimental and control. The experimental group was based on the second stage of implant uncovery with a 940nm diode laser, and the control group included the second stage with an 810 nm diode laser. Indicators such as the need for local anesthesia and the amount of anesthesia injected during surgery, the duration of surgery, the amount of bleeding during surgery, pain, inflammation, edema, and the color of the gingiva in the surgical area, were compared in two study groups during surgery.

**Results:** The independent t-test showed no significant difference in the average duration of surgery in the two groups (31.3 and 37.6 seconds in the 940nm and 810nm wavelength of the diode laser, respectively,  $P=0.073$ ). On day zero and day seven after surgery, pain intensity with 810nm diode laser wavelength was higher than with 940 wavelengths. The average amount of anesthesia injected during surgery of the surgical group with a wavelength of 940 nm was significantly lower than that of the 810nm diode laser. No bleeding was observed in both surgery groups.

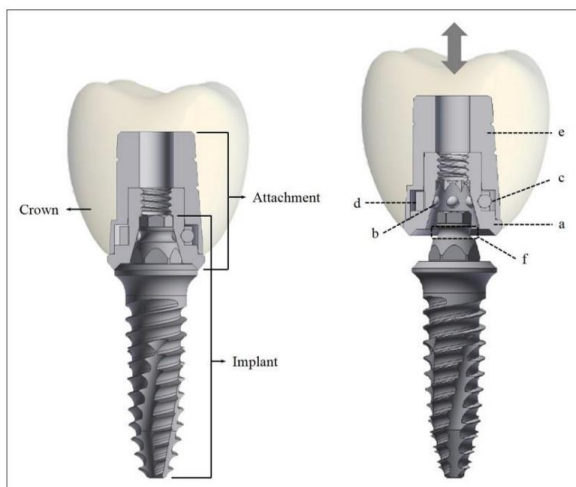
**Conclusion:** The 940nm diode laser had better results than the 810nm in the second stage of implant uncover.

**Keywords:** Oral Soft Tissue; Surgery; Dental Implants; Wavelength; Diode Laser.

## 1. Introduction

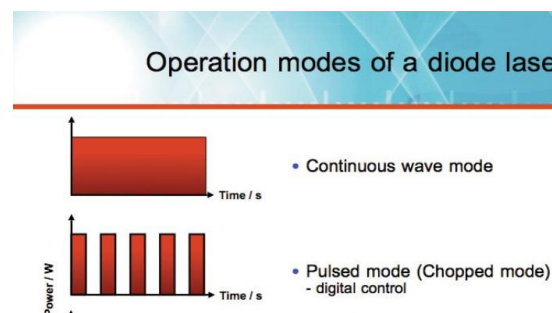
Dental implants are the best choice for replacing missing teeth [1]. The attempt for implanted material to replace missing teeth goes back to the ancient Egyptians [2]. The body of the implant (fixture) is divided into three parts, including crestal (neck), middle, and apex, and special considerations should be considered in the design of each one [3]. The newly developed micro-locking implant prosthetic system consists of an assembly-type attachment and a one-piece implant [4] (Figure 1). Two stages are involved in one implant surgery method. The gingiva is moved back to a limited extent from the dental implant area in the second stage after about two months for lower and three months for upper jaw implants. The covering screw is opened, and the extra maxillary part of the implant or the screw of the gingival former is closed to form the surrounding gingiva. Removal of hyperplastic tissue around the implant can be performed with a surgical blade, electro-surgery, or laser radiation [5, 6]. The electro-surgery can severely destroy the implant's surface, damage the bone, and fail [7]. A diode laser eliminates the need for local anesthesia to be effectively used for the second stage of implant surgery. Using this laser for uncovering stage of the implant provides additional benefits for the patient and the dentist over conventional methods [8].

Lasers are advantageous because they provide precise control over exposure to soft tissue, resulting



**Figure 1.** Different parts of the implant [4]. (a) Body; (b) ball involved in retention; (c) ball involved in preventing spring rotation; (d) spring; (e) cap; (f) retention groove

in penetration to three to five layers. However, the diode laser is unsuitable for cutting hard tissue such as teeth and bones due to the wavelength and target molecules [5]. Each type of laser uses different materials to produce different wavelengths of light [8-10]. Diode laser usually operates between two wavelengths of 810 to 980 nm. The CO<sub>2</sub> laser produces a wavelength of about 10,600 nm, ND: YAG lasers produce a wavelength of about 1,064, and ER: YAG usually produces a wavelength of 2,940 nm. In addition, the diode laser is slightly absorbed by titanium, and the temperature of the implant body does not significantly increase when detected by the laser. Diode lasers can be manufactured with different wavelengths. Laser surgery relies heavily on these features. Any laser with these features can be minimally invasive and used in all surgeries. Thus, the diode laser can be used in various surgical specialties with the least invasiveness. Figure 2 shows the operating modes of the diode laser. In summary, a 980nm diode laser can safely remove the soft tissue around the implant, but its limitations (low cutting depth, low cutting speed) should be considered [11].



**Figure 2.** Diode laser operation modes [14]

Hossein *et al.* showed a significant difference in the two groups by investigating using a 970 nm diode laser for implant uncovering on 50 patients whose implants were completely osseointegrated. The differences were regarding the anesthesia requirement, surgery duration, postoperative pain, and recovery time, which were significantly lower in the diode laser-treated group [12]. The results of another study stated that the use of diode, KTP, Er: YAG, and Nd: YAG lasers with four wavelengths of 532, 810, 1,064, and 2,940 nm on four pig jaw bones with five implants did not show any dangerous temperature increase to the tissue and implant [13].

Other studies have also shown that this technique is a practical, comfortable, and safe method for faster

recovery in the second phase of surgery [15]. The present study investigates the clinical tissue healing around the gingival former of dental implants following the uncovering of the area with two different diode laser wavelengths (810 and 940 nm). The other objective was to find a better wavelength in pain intensity, surgery duration, and bleeding in this stage. The use of a diode laser eliminates the need for local anesthesia, so it can be effectively used for the second stage of implant surgery, and when it is used to expose the implant, it gives additional benefits to the patient and the dentist over conventional methods. Few researches have been done in the investigation of the use of different types of laser wavelengths for the second stage of implant surgery. This research aimed to find the best wavelength of the diode laser in the amount of pain, duration of surgery, and bleeding during revealing the area around the gingival former implant.

## 2. Materials and Methods

This controlled clinical trial examined patients referred to the Department of Periodontology, Faculty of Dentistry, Jundishapur University of Medical Sciences in Ahvaz, Iran, and the dental office in 2015-2016. The inclusion criteria were patient satisfaction, suitable jaw anatomy for implant placement, absence of systemic disease, the superiority of the implant over other replacement treatments regarding the treatment plan, and insufficient keratinized gingiva (in cases of laser use). The exclusion criteria included a systemic diseases history, patients with immune system disorder, improper control plate, smoking, pathological symptoms such as periapical radiolucency of adjacent teeth in areas close to the implant, periodontal diseases, bone cysts, poor cooperation and lack of sufficient keratinized gingiva. Patients were first evaluated regarding systemic considerations and complete blood tests. The studied patients were referred for the second stage of implant surgery (uncovery) and met all the above conditions. Additionally, the Periodontology department of the Faculty of Dentistry was consulted for patients who underwent healing implant placement and had satisfactory osseointegration. Before surgery, the patient was given the necessary information about this study, and written consent was obtained. The patients were divided into two surgical groups with 940nm

(study group) and 810nm laser (control group). The first study group included 36 patients. For these patients, a 940nm diode laser was used for the second stage of the implant surgery.

Before surgery, the patient was given the necessary information about this study, and written consent was obtained. The patients were divided into two surgical groups with 940nm (study group) and 810nm laser (control group). The first study group included 36 patients. For these patients, a 940nm diode laser was used for the second stage of the implant surgery. Then, 2% lidocaine with 1:100,000 epinephrine was used in the required amount to relieve pain during surgery. The control group also included 36 patients who underwent surgical uncovering of the second stage of the implant with an 810nm laser under local anesthesia with the injection of 2% lidocaine infiltrate with epinephrine 1:100,000 in the required amount. A periodontal probe was utilized to evaluate the exact location of the implant Before starting the surgery.

The lasers used for uncovering the cover screw were 940nm in the experimental group and 810nm in the control group. During the surgery, the laser radiation was stopped for 15-20s to prevent a temperature increase in the bone and surrounding soft tissue. Suction improved the surgeon's vision and access during the operation. Lasers were used to create small openings, then increased until part of the cover screw was identified. The tissue above the implant was resected until the size of the surgical valve was sufficient to remove the screw. After this step, the implant cover screw was removed, and a suitable healing abutment was placed. Patients who have pain after treatment should take Ibuprofen 400 mg every six hours. The patient was asked to return on the seventh day after surgery to check the wound healing.

During surgery, the need for local anesthesia and the amount of anesthesia injected during surgery (using a graduated ruler and converting its value in mm), the duration of surgery (using a chronometer), the amount of bleeding during surgery (four categories: zero = no bleeding, one=minimal bleeding, two = normal bleeding, three = excessive bleeding), pain (using visual analogue scale VAS: Visual analogue scale zero = no pain to ten = worst imaginable pain), inflammation, edema and the gingival color of the surgical area. In addition, the

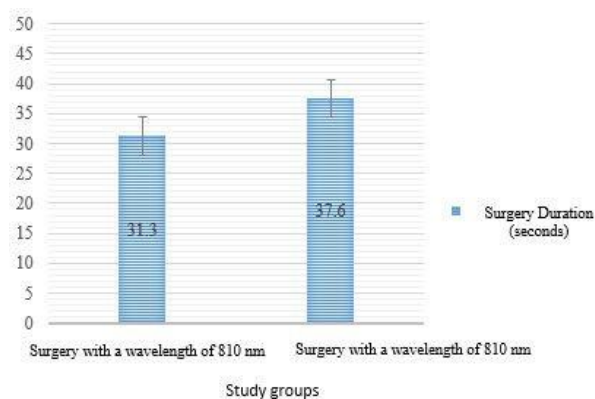
patient was asked to report the number of painkillers consumed in the post-surgery period.

### 2.1. Data Analysis

A t-test compares two groups when the data is normal, and a Mann-Whitney test is used when the data is not normal. Kido is also used to compare qualitative variables in both groups. Logistic regression was used to compare the simultaneous effect of variables in two groups. SPSS statistical software was used to analyze the obtained data. The significance level in the comparison of means was 0.05. Additionally, the examination results, the subject identity, the patients' names, and all their information are entirely confidential and are used only for research purposes. The research results are generally published as the study group information. The results are provided without mentioning individual names and specifications.

### 3. Results

The mean and standard deviation of the surgery duration were  $31.3 \pm 13.03$  and  $37.6 (15.9)$  seconds in the 940nm diode laser group and the surgical group with 810nm wavelength of the diode laser, respectively. The independent t-test also showed no significant difference in the average duration of surgery in the two groups ( $P=0.073$ ) (Figure 3)



**Figure 3.** The study groups' average based on the surgery duration

Additionally, Table 1 shows the results based on pain intensity after surgery.

The results of the chi-square test ( $\chi^2$ ) showed a significant difference in the two surgical groups in pain intensity both on day zero after surgery ( $P=0.002$ ,  $\chi^2=23.1$ ) and on the seventh day after surgery ( $P=0.029$ ,  $\chi^2=7.1$ ). According to the reported frequency and percentages of pain intensity in Table 1, on day zero and day seven after surgery, pain intensity with 810nm diode laser wavelength was higher than with 940 wavelengths. The mean, standard deviation, and comparison of two surgical groups with wavelengths of 940 and 810nm diode laser following area uncovering in the amount of injected anesthesia during surgery (in mm) are reported in Table 2.

**Table 1.** Comparison based on pain intensity after surgery

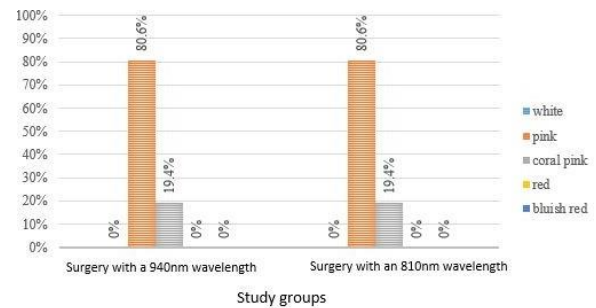
Day	Degree of pain	Studied groups				Chi-square <sup>test</sup> results ( $\chi^2$ )		
		Wavelength 940 nanometers		Wavelength 810 nanometers		the chi-square statistic	df	P-value
		Abundance	Percent	Abundance	Percent			
Zero	0	12	33.3	10	27.8	**23.1	7	0.002
	1	10	27.8	3	8.3			
	2	5	13.9	13	36.1			
	3	0	0	2	5.6			
	5	0	0	3	8.3			
	6	6	16.7	1	2.8			
	7	3	8.3	0	0			
	10	0	0	4	11.1			
	Total	36	100	36	100			
Seventh after surgery	0	27	75	29	80.6	*7.1	2	0.029
	1	9	25	3	8.3			
	2	0	0	4	11.1			
	Total	36	100	36	100			

\*\* $P<0.01$ , \* $P<0.05$

**Table 2.** The study group comparison based on the injected anesthesia amount during surgery

	Studied groups				Mann-Whitney test results		
	Wavelength 940 nanometers		Wavelength 810 nanometers		Mann-Whitney statistic value	Z score	P-value
	Average	The standard deviation	Average	The standard deviation			
injected anesthesia	0.099	0.034	0.224	0.019	1	-7.3	0.0000

The Mann-Whitney test showed a significant difference in the average amount of injected anesthesia during surgery in the two groups ( $P < 0.01$ ). The average amount of anesthesia injected during surgery of the surgical group with a wavelength of 940 nm was significantly lower than that of the 810nm diode laser. No bleeding was observed in both surgery groups with 940 and 810 nm diode laser wavelengths following area uncovering during surgery. No difference was observed between the groups with 940 and 810nm wavelengths. Frequency, frequency percentage, and comparison of two surgery groups with the wavelength of 940 and 810 nm diode laser following the uncovering of the area based on the color of the gingiva after surgery are shown in Table 3.

**Figure 4.** Frequency percentage of study groups based on the color of gingiva after surgery (seventh day)**Table 3.** The study group comparison based on the color of the gingiva after surgery

Day	Color	Studied groups				Chi-square <sup>test</sup> results ( $\chi^2$ )		
		Wavelength 940 nanometers		Wavelength 810 nanometers		the chi-square statistic	df	P-value
		Abundance	Percent	Abundance	Percent			
Seventh after surgery	white	36	100	36	100	---	--	---
	Total	36	100	36	100			
	pink	29	80.6	29	80.6	0.000	1	0.001
	coral pink	7	19.4	7	19.4			
	Total	36	100	36	100			

\*\* $P < 0.01$ , \* $P < 0.05$

On day zero, the gingival color was white after surgery in all samples of both surgery groups, making the chi-square test impossible and indicating the lack of difference in both groups on day zero. The chi-square test ( $\chi^2$ ) results showed no significant difference in the two surgical groups on the seventh day after surgery ( $P = 1.00$ ,  $\chi^2 = 0.000$ ), and both groups were completely similar in the color of the gingiva (Figure 4).

## 4. Discussion

The studies on the diode laser wavelengths are based on different tissue settings, which sometimes contradict each other. Their effects on soft tissue are similar, so a slight difference can be seen in water absorption only by increasing the wavelength. Azizi *et al.* [16] in Iran compared two types of 810 and 980nm diode lasers in resecting gingival pigmentation on 24 patients (one quadrant was 810 and the other quadrant was 980). Photographs were taken before, two, four,



and six weeks after the intervention. Based on the reports, the pigmentation area and perimeter were not significantly different before, two, four, and six weeks after the surgery with 810 and 980nm lasers. The lack of difference is due to the almost identical characteristics of these two types of lasers, which were not clinically significant. Any of these two lasers had an advantage over the other for treating gingival pigmentation. From a statistical point of view, the inconsistency of these results with ours may be due to the different variables and lack of examining the pain and recovery variables in this study. A case report was conducted by Karanth *et al.* [17] in India to treat pyogenic granuloma in a 46-year-old woman using a 940nm diode laser. In this report, the patient expressed great comfort during surgery. The surgery was almost bloodless, painless, and without needles. The results were consistent with the present study regarding the absence of bleeding during and after surgery and no pain in the 940nm laser. Carlo Fornaini studied calf tongue in 205 in Italy to compare four different wavelengths of 810, 980, 1470, and 1950nm diode laser effects on the internal temperature of the soft tissue close to the beam. The results showed that the 1950nm laser had the lowest temperature increase, and the 1950nm laser had the highest quality and cutting speed due to its high tendency to absorb water. The best operating wavelengths in the laboratory study were 1470 and 1950nm, which caused the least vascular and epithelial damage.

According to this study, the longer wavelength of the diode causes less vascular and epithelial damage, and, as a result, the patient experiences less pain. Also, a study by Sarker *et al.* (2015) was conducted in India comparing the 940 nm diode laser effect and Er, Cr: YSGG (2780 nm) in the oral leukoplakia treatment in five 18-year-old patients. In this study, using a 940 nm diode laser caused minimal and sometimes no pain, which caused excellent hemostasis and good wound healing without complications after the operation.

In comparison, Er, Cr: YSGG caused minimal pain and discomfort, excessive bleeding during surgery, and good healing.

In the one-year follow-up, no recurrence was seen in the treatment with these two lasers.

The present study showed that the reported pain by the patients was less with the diode laser. Finally, it

was concluded that the 940nm diode laser is superior to Er, Cr: YSGG (2780 nm) during the oral leukoplakia treatment, but both can be used for its treatment [12].

The results of this study are consistent with ours regarding the superiority of the 940nm diode laser for minimal pain, bleeding, discomfort, and good recovery. In a study conducted by Chandragupta *et al.* (2014) in India, a 72-year-old man was treated with a 940nm diode laser for hypertrophic tissue in areas 47 and 48 of the jaw. The study results were as follows:

Providing a sterilized surgical area, more precise surgical incisions, wound healing without the need for patches or sutures, the surgical area without bleeding, and as a result, surgeon better vision, bacteria reduction in the surgical area, easy recovery period, no need for drugs, more comfort (less pain and edema, less bleeding after surgery) with well-healed tissues (without scars, shrinkage, discoloration, and anatomical changes after surgery) [18]. The present study is consistent with ours on the benefits of a 940nm diode laser. Previous studies have shown that diode laser can be used in the mouth soft tissue and minimal prominent lesions surgeries due to ease of use, better coagulation, no need for sutures, less pain, edema, and treating physiological gingival pigmentation due to aesthetic results.

Moreover, it was previously stated that Er: YAG laser has little effect on temperature increase, and CO<sub>2</sub> laser and diode showed good tissue quality. On the other hand, previous studies have revealed that dental laser treatment is a successful method with good aesthetic results, correct tissue formation, function, and bio compatibility.

Geminiani *et al.* in America studied temperature changes during non-contact diode laser irradiation to the implant surface using two 810 and 980nm diode lasers with 2W power and two thermocouples to record temperature (in cervical and apical).

In this study, the 810nm laser showed a 10C temperature increase after 14 and the 980 nm laser showed this after 12 seconds. Thus, diode laser radiation to the implant surface could cause a temperature increase above the critical threshold (10°C) after only 10s, and there is a possibility of bone damage. Special care should be taken due to the higher penetration depth of the diode. The inconsistency of these results with the present study may be due to the

different depths of implant placement because the 980 nm laser increases the surface temperature more. Another study stated that diode lasers resulted in patient satisfaction and rapid tissue repair, in agreement with the present study results [19, 20]. The previous studies also showed the positive effects of this laser in line with our study results on diode laser safety.

The effects mentioned above included good cutting ability, no need for anesthesia, good healing, increased homeostasis, and minimal damage to the soft tissue and underlying bone. As a result, diode laser was recognized as an effective substitute in oral soft tissue surgeries [16, 18, 21].

## 5. Conclusion

Based on the results, the 940 nm diode laser had better results than the 810 nm in the second stage of implant uncover.

## References

- 1- Mohammad Mohammadi, Mohammad Ali Shokrgozar, and Rasool Mofid, "Culture of human gingival fibroblasts on a biodegradable scaffold and evaluation of its effect on attached gingiva: A randomized, controlled pilot study." *Journal of periodontology*, Vol. 78 (No. 10), pp. 1897-903, (2007).
- 2- Luiz Otavio Rocha, Eduarda Rocha, Guilherme de Menezes Succi, and Rui Barbosa de Brito Junior, "Association between Periodontitis, Genetic Polymorphisms and Presence of Coronary Artery Disease in Southern Brazil." *Arquivos brasileiros de cardiologia*, Vol. 114pp. 268-72, (2020).
- 3- Bahram Jafari, Hamid Reza Katoozian, Masoud Tahani, and Nima Ashjaee, "A comparative study of bone remodeling around hydroxyapatite-coated and novel radial functionally graded dental implants using finite element simulation." *Medical Engineering & Physics*, Vol. 102p. 103775, (2022).
- 4- Jae-Won Choi et al., "Load-bearing capacity and retention of newly developed micro-locking implant prosthetic system: An in vitro pilot study." *Materials*, Vol. 11 (No. 4), p. 564, (2018).
- 5- Muhamed I Hazeem, Muthenna Sh Rajab, and Raed A Badeia, "Treatment of recurrent aphthous stomatitis with 940nm diode laser." *Tikrit Journal for Dental Sciences*, Vol. 3 (No. 1), (2014).
- 6- Jeffrey D Pope, Jeffrey A Rossmann, David G Kerns, M Miles Beach, and Daisha J Cipher, "Use of a carbon dioxide laser as an adjunct to scaling and root planing for clinical new attachment: a case series." *Clinical Advances in Periodontics*, Vol. 4 (No. 4), pp. 209-15, (2014).
- 7- Karin Kobuch et al., "Implantation of Biosynthetic Collagen III Corneal Implants in vivo in Rabbit Eyes: Surgical Technique and Clinical Performance." *Investigative Ophthalmology & Visual Science*, Vol. 54 (No. 15), pp. 3474-74, (2013).
- 8- KE El-Kholey, "Efficacy and safety of a diode laser in second-stage implant surgery: a comparative study." *International journal of oral and maxillofacial surgery*, Vol. 43 (No. 5), pp. 633-38, (2014).
- 9- Nihat Akbulut, E Sebnem Kursun, M Kemal Tumer, Kivanc Kamburoglu, and Ugur Gulsen, "Is the 810-nm diode laser the best choice in oral soft tissue therapy?" *European journal of dentistry*, Vol. 7 (No. 02), pp. 207-11, (2013).
- 10- Samo Pirnat, "Versatility of an 810 nm diode laser in dentistry: An overview." *J Laser Health Acad*, Vol. 4 (No. 2), pp. 1-9, (2007).
- 11- Josep Arnabat-Domínguez, Antonio Jesús España-Tost, Leonardo Berini-Aytés, and Cosme Gay-Escoda, "Erbium: YAG laser application in the second phase of implant surgery: a pilot study in 20 patients." *International Journal of Oral & Maxillofacial Implants*, Vol. 18 (No. 1), (2003).
- 12- Alessandro Geminiani, Jack G Caton, and Georgios E Romanos, "Temperature change during non-contact diode laser irradiation of implant surfaces." *Lasers in Medical Science*, Vol. 27pp. 339-42, (2012).
- 13- MBF Amaral, JMS De Ávila, MHG Abreu, and RA Mesquita, "Diode laser surgery versus scalpel surgery in the treatment of fibrous hyperplasia: a randomized clinical trial." *International journal of oral and maxillofacial surgery*, Vol. 44 (No. 11), pp. 1383-89, (2015).
- 14- Andrey V Belikov, Alexei V Skrypnik, and Ksenia V Shatilova, "Comparison of diode laser in soft tissue surgery using continuous wave and pulsed modes in vitro." *Frontiers of Optoelectronics*, Vol. 8pp. 212-19, (2015).
- 15- Kawe Goharkhay et al., "Effects on oral soft tissue produced by a diode laser in vitro." *Lasers in Surgery and Medicine: The Official Journal of the American Society for Laser Medicine and Surgery*, Vol. 25 (No. 5), pp. 401-06, (1999).
- 16- A Azizi, H Ebrahimi, N CHini Foroush, and S GHolami, "The comparison between efficacy of 980 and 810 nanometer Diode Laser on gingival pigmentation removal." *Res Dent Sci*, Vol. 13 (No. 1), pp. 1-7, (2016).
- 17- Sharath Karanth, Deepa Shetty, M Hemanth, Manoj Varma, and Benette Fernandes LavanyaVarma, "Case Report Treatment of pyogenic granuloma using a 940nm Diode laser."
- 18- Elisabetta Merigo et al., "Laser-assisted surgery with different wavelengths: a preliminary ex vivo study on thermal increase and histological evaluation." *Lasers in Medical Science*, Vol. 28pp. 497-504, (2013).

- 19- Semez Gianfranco, SE Francesco, and Rocca Jean Paul, "Erbium and diode lasers for operculisation in the second phase of implant surgery: A case series." *Timisoara Med J*, Vol. 60 (No. 1), pp. 117-23, (2010).
- 20- Ena Mathur, Mohit Sareen, Payal Dhaka, and Pallavi Baghla, "Diode laser excision of oral benign lesions." *Journal of lasers in medical sciences*, Vol. 6 (No. 3), p. 129, (2015).
- 21- Debanti Giri, Nitin Agarwal, Abhishek Sinha, Sunita Srivastava, and Anuj Mishra, "Diode laser: In treatment of recurrent verrucous leukoplakia." *Contemporary Clinical Dentistry*, Vol. 7 (No. 2), p. 250, (2016).