


Functional MRI Investigation of Memory and Language in Temporal Lobe Epilepsy

Zhamak Akhlaghi^{1,2}, Narges Hoseini Tabatabaei³, Alireza Fallahi⁴, Fatemeh Eivazi⁵, Neda Mohammadi Mobarakeh⁶, Babak Babakhani⁷, Saeed Masoudnia^{1,8}, Seyed Sohrab Hashemi-Fesharaki⁹, Jafar Mehvari Habibabadi¹⁰, Mohammad-Reza Nazem-Zadeh^{1,11*} 

¹ Research Center for Molecular and Cellular Imaging, Tehran University of Medical Sciences, Tehran, Iran

² Department of Medicine, Division of Clinical Pharmacology, Johns Hopkins School of Medicine, Baltimore, MD, USA

³ Medical School, Tehran University of Medical Sciences, Tehran, Iran

⁴ Biomedical Engineering Department, Hamedan University of Technology, Hamedan, Iran

⁵ Shahid Beheshti University, Institute for Cognitive and Brain Sciences, Tehran, Iran

⁶ Department of Medical Physics and Biomedical Engineering, School of Medicine, Tehran University of Medical Sciences, Tehran, Iran

⁷ Brain and Spinal Cord Injury Research Centre, Neuroscience Institute, Tehran University of Medical Sciences, Tehran, Iran

⁸ School of Cognitive Sciences, Institute for Research in Fundamental Sciences, Tehran, Iran

⁹ Pars Advanced Medical Research Center, Pars Hospital, Tehran, Iran

¹⁰ Isfahan Neuroscience Research Center, Isfahan University of Medical Sciences, Isfahan, Iran

¹¹ Research Fellow, Department of Neuroscience, Monash University, Victoria, Australia

*Corresponding Author: Mohammad-Reza Nazem-Zadeh Received: 13 August 2025 / Accepted: 28 April 2026

Email: Mohamad.Nazem-Zadeh@monash.edu

Abstract

Purpose: Language and memory impairments are common in temporal lobe epilepsy (TLE), yet few studies have examined both domains within the same cohort using task-based functional MRI (fMRI). Comprehensive mapping of these functions is essential for accurate localization of seizure foci and for presurgical evaluation. Identifying compensatory mechanisms is particularly important, as many TLE patients retain normal cognitive performance despite structural pathology.

Materials and Methods: We examined 21 left TLE (LTLE) and 14 right TLE (RTLE) patients, along with 17 Healthy Controls (HC), using eight task-based fMRI paradigms assessing verbal and non-verbal memory (encoding and retrieval) and language processing (phonetic and semantic verbal fluency, verb generation, and passive listening). Also, all participants underwent the CANTAB® neuropsychological test.

Results: Compared with HC, TLE patients showed increased activation in the left temporal lobe and parahippocampal gyrus during non-verbal memory encoding, and in the left precuneus and right parahippocampal gyrus during retrieval ($P < 0.05$). Verbal memory tasks elicited enhanced activation in the bilateral frontal lobes for both encoding and retrieval and in the left cingulate gyrus during retrieval ($P < 0.05$). Importantly, no significant activation differences were detected between LTLE and RTLE across memory and language tasks ($P > 0.05$). Instead, both groups demonstrated broadened and bilateral activation patterns relative to controls, consistent with compensatory reorganization. Language tasks further showed extensive recruitment of the inferior frontal gyrus, superior temporal gyrus, and supplementary motor areas in the TLE.

Conclusion: TLE patients exhibited a widespread and bilateral redistribution of both memory and language networks, despite comparable task performance to healthy controls. These findings indicate robust compensatory functional reorganization involving temporal, frontal, and supplementary regions. An integrated language–memory fMRI paradigm can, therefore, capture clinically meaningful reorganization in TLE and may assist in presurgical functional mapping and cognitive risk assessment.

Keywords: Temporal Lobe Epilepsy; Task-Based functional Magnetic Resonance Imaging; Memory and Language Mapping.

1. Introduction

Temporal Lobe Epilepsy (TLE) is a common type of refractory focal epilepsy, for which surgical treatment has proven to be effective [1]. Task-based fMRI is a widely used, non-invasive, and accurate method for preoperative localization and lateralization of language and memory networks. It identifies Broca's and Wernicke's areas and language dominance [2-4]. While also correlating verbal and nonverbal memory deficits with left and right TLE, enabling clear lateralization profiles [5-7]. Understanding compensatory mechanisms is clinically important, as many TLE patients maintain relatively preserved cognitive function despite mesial temporal pathology. Early identification of such mechanisms can clarify how functional networks reorganize in response to chronic seizures.

Neuropsychological and fMRI studies highlight the key role of the Medial Temporal Lobe (MTL) and Prefrontal Cortex (PFC) in memory encoding and retrieval [8]. The amygdala, hippocampus, and parahippocampal regions are crucial; damage to these regions can cause amnesia [9]. In drug-resistant mesial Temporal Lobe Epilepsy (mTLE), MTL involvement varies, influencing both explicit memory and language functions through distinct activation patterns [6, 10]. Functional MRI studies have demonstrated that increased activation in the Medial Temporal Lobe (MTL) during memory consolidation highlights its crucial role in supporting both explicit and other distinct types of memory [11, 12] and implicit memory [13-16].

Previous work has used modified Powell stimuli to examine encoding processes, for example, comparing visual scenes with scrambled images or presenting concrete nouns and colored pictures against a fixation baseline while participants made like/dislike judgments to encourage deep encoding [17]. Although such studies characterize general memory-encoding mechanisms, they have not addressed how these processes differ in clinical populations. There are several works concerning the prognosis of cognitive functions among patients undergoing epilepsy surgery [18-20]. However, despite the central role of the temporal lobe in both memory and language, the combined effects of temporal lobe resection on the behavioral and neural substrates underpinning these

functions remain insufficiently understood [21]. To address this gap, our study directly compares TLE patients and healthy controls on language and both visual and verbal memory tasks during encoding and retrieval, allowing us to assess how TLE alters large-scale functional organization across language and memory systems.

This study aimed to assess brain activity in TLE patients using task fMRI and neuropsychological evaluations. Accordingly, eight tasks, including Word/Picture Encoding and Retrieval, Phonetic Verbal Fluency (PVF), Semantic Verbal Fluency (SVF), Passive Listening (PL), and Verb Generation (VG), were used to evaluate memory and language-related brain areas and reorganized functional networks.

2. Materials and Methods

2.1. Subject Characteristics

The study was approved by the Research Ethics Board (Institutional Review Board, IRB) of Tehran University of Medical Sciences, and all participants provided informed consent. A total of thirty-five individuals with TLE (males: females, 16:19; left: right TLE: 21:14; age range, 17-54 years; average age 30.4 years) were studied. In addition, seventeen age- and gender-matched healthy control (HC) subjects (males: females, 8:9; age range, 20-42 years; average age, 28 years) were included in the analysis (Table 1). All the participants were right-handed.

Exclusion criteria: history of major psychiatric illness, prior neurosurgery, MRI contraindications, and severe cognitive impairment ($Z \leq -1.5$). Inclusion criteria: confirmed diagnosis of unilateral TLE, right-handedness, and ability to complete all fMRI tasks.

2.2. Image Acquisition

All subjects were scanned using a 3-Tesla Siemens Magnetom Prisma MRI (Siemens Prisma, Erlangen, Germany) and a 64-channel phased-array head coil with the software version Syngo MR E11 at the Iranian National Brain Mapping Laboratory (NBML).

Anatomic images were acquired using an inversion recovery MPRAGE protocol (Magnetization Prepared

- Rapid Gradient Echo Inversion Recovery)/ Three-dimensional anatomical images were acquired for clinical diagnosis including transverse T1-weighted images (TR = 1840 ms, TI = 900 ms, TE = 3.47 ms, flip angle = 8°, matrix = 256 x 256, slice thickness = 1.0 mm), in-plane resolution=1.0×1.0 mm², pixel bandwidth = 250 Hz/pixel.

T2-FLAIR images were also acquired using 3D-T2-SPACE (Sampling Perfection with Application optimized Contrasts using different flip angle Evolution) with imaging parameters as follows: TR = 5000 ms, TI=1800 ms, TE = 260 ms, flip angle = 120–175°, voxel size = 1.0 mm×1.0 mm× 1.0 mm, matrix = 256×256.

fMRI was acquired using gradient-echo planar images with parameters: Voxel size= 2.8×2.8×2.4 mm, Resolution – iPAT acceleration, (GRAPPA), acceleration factor PE=2, reference lines PE = 24, SNR: 1.00, Slices=53, distance factor = 0 %, phase encoding Direction = A >> P, FoV (read) = 220 mm, FoV (phase) = 100.0 %, Base resolution 80, Phase resolution 100 %, Slice thickness 2.4 mm, TR =3000 ms, TE = 30.0 ms, averages = 1, fPrescan Normalize = on, fat saturation, reconstruction = magnitude, number of measurements = 140, phase partial Fourier= off, interpolation = off, and Prescan Normalize = on.

2.3. Task fMRI Protocols

For memory mapping, four tasks were performed, including Word Encoding, Picture Encoding, Word Retrieval, and Picture Retrieval. Visual stimuli (pictures) and verbal stimuli (words) were presented visually during a single scanning session (Sidhu et al., 2013). The words were either concrete or abstract nouns (length between 2 and 8 characters). The pictures were either concrete (objects) or scenes

selected from the Open Affective Standardized Image Set (OASIS) [22]. The pictures were neutral photos in arousal and valence, based on the OASIS dimensions. The fMRI paradigm consisted of alternating blocks of words for verbal stimuli and pictures for visual stimuli, with each of the 14 blocks preceded by a 30-sec crosshair fixation. Each picture block consists of 6 pictures being presented on screen for 18s, followed by 12s of a blank screen (Figure 1. A). Each word block consists of 6 words being presented on screen for 18s, followed by 12s of a blank screen (Figure 1. B). Participants were instructed to indicate with a button-press whether they liked or disliked each word. They were also asked to memorize the words for a recognition retrieval test following the encoding test, where the memory is evaluated with a “seen”/ “unseen” recognition test. The 70 words presented during scanning were presented again, intermixed with 42 new words as foils.

For language mapping, four tasks were performed, including PVF, SVF, PL, and VG. The fMRI paradigm consisted of alternating blocks. Each block was presented on the screen, followed by a blank screen. For SVF, 7 blocks were used, while for PVF, PL, and VG, 5, 4, and 4 blocks were used, respectively (Figure 2).

In the PVF task, in each block, one Persian letter was shown to the participants, and they were asked to make as many words as they could make from (total scan time = one block duration (30s) × Number of blocks (4) × 2 (task+rest) = 240 s).

In the SVF task, the participants were presented with eight pictures of animals in each block, and were asked to respond through the response grip if a presented animal was a captive-bred meat animal (total scan time = TR (3s) × Number of stimuli (8) × Number of blocks (7) × 2 (task+rest) = 336 s).

Table 1. Summary of participant characteristics

Characteristic	Left TLE	Right TLE	HC	P-Value
Sample size	21	14	17	-
Sex (M/F)	10/11	8/6	8/9	0.73‡
Age (yr), mean ± STD [range]	31.9 ± 8.2 [17-54]	26.8 ± 6. [17-36]	28 ± 6.5 [20-42]	0.059*
Onset Age (yr), mean ± STD [range]	10.8 ± 8.2 [0.5-29]	9.4 ± 9.4 [0.5-28]	-	0.6*

‡ Fisher exact test

* Two-sample test

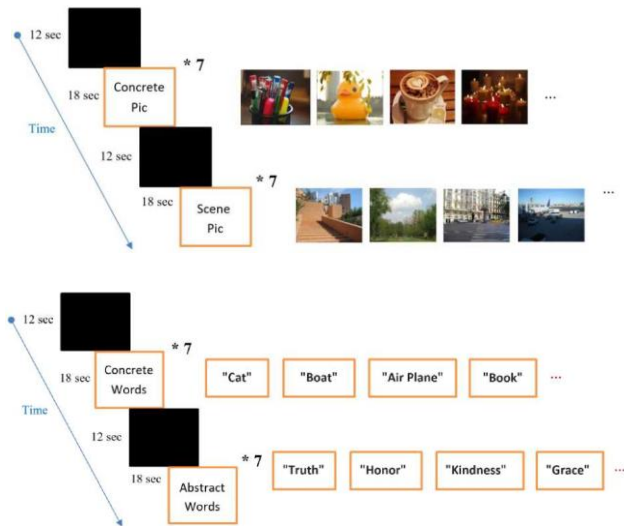


Figure 1. Task Design for Memory Mapping

A: Picture Encoding and Picture Retrieval. Each picture block consists of 6 pictures being presented on screen for 18s, followed by 12s of a blank screen. **B:** Word Encoding and Word Retrieval. Each word block consists of 6 words being presented on screen for 18s, followed by 12s of a blank screen

In the VG task, the participants were shown eight nouns from which they should make associated verbs in each block (total scan time = TR (3s) × Number of stimuli (8) × Number of blocks (4) × 2 (task+rest) = 192 s).

In the PL task, the participants were instructed to listen carefully to a single pre-recorded story in four episodes (i.e., blocks), after which they might have been asked about some details (total scan time = one episode of the story (30s) × Number of episodes (4) × 2 (task+rest) = 240 s).

2.4. Data Analysis

2.4.1. Preprocessing

All fMRI data were analyzed using the fMRI Expert Analysis Tool (FEAT) in FSL (version 6.0.4). Preprocessing began with skull stripping using FSL’s Brain Extraction Tool (BET), followed by motion correction via MCFLIRT. Slice-timing correction was performed using Fourier-space time-series phase-shifting. Functional images were normalized to MNI space in two steps: (1) co-registration to each participant’s T1-weighted image using FLIRT with 7 degrees of freedom (DOF), and (2) linear registration of structural images to MNI space with 12 DOF.

PL	30s 30 s * 4	VG	30s 30 s * 4
PVF	30s 30 s * 5	SVF	24s 24 s * 7

Figure 2. Task Design for Language Mapping

The fMRI paradigm consists of alternating blocks. For SVF, 7 blocks preceded. Each block was presented on the screen for 24s, followed by 24s of a blank screen. For PVF, PL, and VG, 5, 4, and 4 blocks preceded, respectively, each block being presented on screen for 30 seconds, followed by 30 seconds of a blank screen. PVF: Phonetic Verbal Fluency, SVF: Semantic Verbal Fluency, PL: Passive Listening, and VG: Verb Generation

Spatial smoothing was applied using a Gaussian kernel (FWHM = 6.0 mm). Additionally, mean intensity normalization across time points and high-pass temporal filtering (sigma = 60.0s) using Gaussian-weighted least-squares fitting were performed.

2.4.2. First-Level Analysis

First-level analysis was performed for each participant, followed by second level/group analysis. In the first level analysis, the General Linear Model (GLM) was performed using FEAT (version 6.0.4), FSL, for parametric statistical analysis. To make the statistical approaches valid and most efficient, the FILM (FMRIB Improved Linear Model) pre-whitening was utilized for statistical analysis of the fMRI time series. The statistical maps represent voxel-wise z-scores reflecting task-related BOLD activation. A boxcar function of tasks versus rest is created and convolved with a canonical hemodynamic response function and its temporal derivatives. As explained earlier, registration of the estimated functional map to the corresponding structural image and ultimately the MNI space was performed.

2.4.3. Higher-Level Analysis

Group-level analysis was performed under the FLAME procedure (FMRIB’s Local Analysis of Mixed Effects) to estimate within-group averages as well as between-group comparisons. A voxel-level

probability threshold of $z > 2.3$ was applied to reveal significantly activated regions only. A False Discovery Rate ($p\text{-FDR} < 0.05$) was used to correct for multiple comparisons.

2.5. Neuropsychological Testing

In our study, participants underwent neuropsychological assessments covering executive functions, visual recognition memory, manual reaction time, mental and motor speed, and social cognition, conducted by a trained clinical psychologist. Digital tests were administered using the Cambridge Neuropsychological Test Automated Battery (CANTAB®), including the Paired Associates Learning (PAL) task, which evaluates visual memory and new learning by testing participants' ability to remember the location of visual pairs. The second task was Pattern Recognition Memory (PRM), which provides insights into visual recognition abilities, requiring individuals to discriminate between visual patterns. We obtained ten cognitive test scores, including seven from PAL: Total Trials (TT), Total Errors (TE), stages completed on the first trial (SCFT), Mean Trials to Success (MTS), mean errors to success (MES), first trial memory score (FTMS), and total errors 2 (TE2) and three from PRM: mean correct latency (MCL), number of corrects (NC), and percent corrects (PC).

Z-scores represent performance relative to age-adjusted normative data (0 = average; -1.5 SD commonly indicates impairment). Group differences in demographic and neuropsychological measures across LTLE, RTLE, and HC were assessed using one-way ANOVA for continuous variables and Fisher's exact test for categorical variables. When appropriate, post hoc pairwise comparisons were performed with Bonferroni correction. Non-parametric tests were used when normality assumptions were not met.

3. Results

3.1. Active Brain areas in Memory Tasks

3.1.1. Non-Verbal Memory

In TLE patients, we observed significantly increased activation in the left temporal lobe and

parahippocampal gyrus during non-verbal memory encoding, suggesting neuroplastic changes compensating for impaired regions (Bonferroni corrected $p < 0.05$; Table 2). During retrieval, heightened activation was found in the left precuneus and right parahippocampal gyrus, indicating adaptive recruitment to support memory function. Although frontal and parietal lobe involvement was reduced compared to healthy controls, memory functionality appeared preserved through alternative network engagement. These findings highlight the brain's capacity for plasticity and reorganization in response to TLE-related damage (Bonferroni corrected $p < 0.05$; Table 2).

3.1.2. Verbal Memory

In verbal memory tasks, TLE patients showed increased frontal lobe and left cingulate gyrus activation during encoding and retrieval, suggesting compensatory reorganization to support memory functions disrupted by epilepsy (Bonferroni corrected $p < 0.05$; Table 3).

3.2. Active Brain Areas in Language Tasks

General Findings: Both TLE patients and healthy controls showed activation in traditional language areas, such as the superior temporal gyrus and middle frontal gyrus. However, TLE patients demonstrated broader and more extensive activation patterns, indicating compensatory recruitment of additional brain regions to support language functions. This wider activation suggests that the brain is utilizing alternative neural pathways to maintain language abilities despite the presence of epilepsy.

Specific Activations: In TLE patients, there was increased activation in regions not typically associated with primary language processing, such as the cerebellum, posterior cingulate gyrus, and additional frontal regions. This enhanced activation points to brain plasticity, where these regions adapt to support language processing, thereby compensating for the impaired areas (Bonferroni corrected $p < .05$; Tables S.1, S.2, and S.3, Figure 3).

3.3. Neuropsychological Tests Assessment

Table 4 shows the mean and standard deviation of z-score values for each neuropsychological test. Figure 4 shows a box plot comparing the CANTAB

tests between the left and right TLE groups. There were no significant differences ($p > 0.05$) between the right and left TLE groups in any of the tests.

Table 2. Comparison of the TLE and Healthy Control groups in the Non-Verbal Memory Task

Group	Non-Verbal Memory Task	Cluster region	Cluster size (Voxels)	Z Score
HC	Concrete Picture Encoding	R. Lingual gyrus	8815	9.42
	Scene Picture Encoding	R. cuneus	20560	6.47
	Concrete Picture Retrieval	Occipital lobe	2804	3.83
	Scene Picture Retrieval	L. Inferior occipital gyrus R. Middle frontal gyrus	14393 1345	5.32 4.14
TLE	Concrete Picture Encoding	R. Precuneus L. Lingual gyrus	2179 1147	6.58 7.64
	Scene Picture Encoding	R. Lingual gyrus	9411	4.65
	Concrete Picture Retrieval	L. Lingual gyrus	808	3.36
	Scene Picture Retrieval	R. Lingual gyrus L. Cerebellum	7914 794	5.19 3.56
HC > TLE	Concrete Picture Encoding	L. Frontal lobe	1258	4.81
	Scene Picture Encoding	R. Fusiform gyrus	22775	5.04
	Concrete Picture Retrieval	L. Postcentral gyrus	652	3.48
	Scene Picture Retrieval	L. Inferior frontal gyrus L. Inferior parietal lobe R. Occipital lobe R. Parietal lobe L. Medial frontal gyrus	9337 2715 1585 1273 788	4.84 4.3 4.74 4.23 4.52
TLE > HC	Concrete Picture Encoding	L. Temporal lobe R. Cuneus L. Parahippocampal gyrus	1272 967 865	7.05 7.43 5.58
	Scene Picture Encoding	L. Parahippocampal gyrus	10622	4.96
	Concrete Picture Retrieval	L. Lingual gyrus L. Precuneus	7737 1179	4.31 3.77
	Scene Picture Retrieval	R. Parahippocampal gyrus	12746	4.88
	Scene Picture Retrieval	L. Inferior frontal gyrus	997	3.99

Left-TLE	Concrete Picture Encoding	L. Cerebellum	16119	5.6
	Scene Picture Encoding	R. Middle occipital gyrus	11468	4.32
	Concrete Picture Retrieval	R. Cerebellum	16062	4.63
	Scene Picture Retrieval	L. Inferior occipital gyrus	8748	4.34
Right-TLE	Concrete Picture Encoding	R. Cerebellum	15749	4.63
	Scene Picture Encoding	L. Inferior frontal gyrus	998	3.99
	Concrete Picture Retrieval	R. Lingual gyrus	6749	4.66
	Scene Picture Retrieval	L. Cerebellum	859	3.72
Left- TLE > Right-TLE	Concrete Picture Encoding	L. Cingulate gyrus	6969	4.2
		L. Fusiform gyrus	1358	4.2
		R. Fusiform gyrus	956	4.03
		L. Inferior parietal lobe	885	3.99
	Scene Picture Encoding	R. fusiform gyrus	1103	3.98
	Concrete Picture Retrieval	R. frontal lob	3323	4.13
		L. Frontal lobe	2304	3.9
		L. Medial frontal gyrus	2063	3.84
		R. Cerebellum	1399	4.4
		L. Frontal lobe	680	3.75
R. Uncus		572	4.03	
Scene Picture Retrieval	L. Inferior frontal gyrus	997	3.99	
Right-TLE > Left-TLE	Concrete Picture Encoding	L. Cuneus	8330	4.51
		L. Paracentral lobule	717	3.96
	Scene Picture Encoding	-----	-----	-----
	Concrete Picture Retrieval	R. Posterior cingulate gyrus	13662	5
	Scene Picture Retrieval	L. Cerebellum	859	3.72
L. frontal lobe		566	3.65	

HC: healthy control; TLE: temporal lobe epilepsy; R: right; L: left

4. Discussion

Following injury, the brain can reorganize by forming new neural connections. In TLE, this adaptability enables recruitment of additional cortical regions to support cognitive function. None of the patients in our cohort showed significant cognitive impairment (Z -score ≤ -1.5), suggesting preserved functional capacity and the

presence of compensatory neural mechanisms. Using task-based fMRI, we assessed both verbal and non-verbal memory and multiple language processes in TLE patients compared with healthy controls. While the involvement of hippocampal and prefrontal regions was expected, our findings revealed prominent contributions from additional temporal, frontal, parietal, and cerebellar regions that support memory and language in both groups.

Table 3. Comparison of the TLE and Healthy Control groups in the Verbal Memory Task

Group	Verbal Memory Task	Cluster region	Cluster size(Voxels)	Z Score
HC	Concrete Word Encoding	L. Cerebellum	679	3.36
	Abstract Word Encoding	R. Cerebellum	11715	5.37
		L. Middle frontal gyrus	2489	4.83
		L. Superior frontal gyrus	1158	4.17
	Concrete Word Retrieval	L. Cerebellum	4481	3.29
		R. Superior parietal lobule	1406	2.73
	Abstract Word Retrieval	R. Lingual gyrus	13468	5.36
		R. Inferior parietal lobule	1626	4.81
R. Middle frontal gyrus		1327	3.76	
TLE	Concrete Word Encoding	R. precentral gyrus	1861	2.76
	Abstract Word Encoding	L. Cerebellum	1821	4.37
	Concrete Word Retrieval	R. Middle frontal gyrus	1004	3.14
	Abstract Word Retrieval	R. Cerebellum	590	4.12
HC>TLE	Concrete Word Encoding	L. Lingual gyrus	1495	3.08
	Abstract Word Encoding	R. Lingual gyrus	1796	4.57
	Concrete Word Retrieval	-----	-----	---
	Abstract Word Retrieval	R. Lingual gyrus	1635	3.88
		L. inferior parietal lobe	1374	3.68
L. Superior parietal lobe	633	4.51		
TLE>HC	Concrete Word Encoding	R. Frontal lobe	3838	2.97
	Abstract Word Encoding	L. Frontal lobe	1856	4.1
	Concrete Word Retrieval	L. Cingulate gyrus	720	3.06
	Abstract Word Retrieval	R. Inferior occipital gyrus	1536	4.09
R. Superior frontal gyrus		713	4.44	
Left-TLE	Concrete Word Encoding	L. Cerebellum	9727	4.89
		L. Inferior frontal gyrus	1587	4.69
		L. Superior frontal gyrus	880	4.07
	Abstract Word Encoding	L. Fusiform gyrus	1220	3.35
	Concrete Word Retrieval	R. Lingual gyrus	9112	4.96
	Abstract Word Retrieval	L. Middle occipital gyrus	3838	4.38
		R. Middle occipital gyrus	1557	3.67
R. Precentral gyrus		561	3.54	
Abstract Word Retrieval	L. Cingulate gyrus	720	3.06	
Abstract Word Retrieval	-----	-----		

Right-TLE	Concrete Word Encoding	L. Cerebellum L. Insula	2341 2245	3.06 3.8
	Abstract Word Encoding	L. Lingual gyrus	6219	3.37
	Concrete Word Retrieval	L. Temporal lobe R. Cerebellum	2476 2136	3.88 4.25
	Abstract Word Retrieval	L. Cingulate gyrus	720	3.06
Left-TLE > Right-TLE	Concrete Word Encoding	R. Lingual gyrus	1709	4.53
	Abstract Word Encoding	----	-----	----
	Concrete Word Retrieval	L. Lingual gyrus	1073	3.47
	Abstract Word Retrieval	----	-----	----
Right-TLE > Left-TLE	Concrete Word Encoding	R. Temporal lobe	1670	4.05
	Abstract Word Encoding	R. Cuneus L. Insula	3132 2411	3.45 3.33
	Concrete Word Retrieval	L. Cingulate gyrus R. Inferior occipital gyrus	1281 1091	4 4.08
	Abstract Word Retrieval	----	-----	----

HC: healthy control; TLE: temporal lobe epilepsy; L: left; R: right

4.1. Memory Tasks (Verbal/Non-Verbal Memory)

4.1.1. Non-Verbal Memory

During non-verbal memory encoding, TLE patients exhibited increased activation in the left temporal lobe and parahippocampal gyrus, consistent with compensatory recruitment for regions typically affected by epileptic pathology. Retrieval engaged the left precuneus and right parahippocampal gyrus, reflecting adaptive reorganization to sustain memory performance. The hippocampus and parahippocampal gyrus are central to episodic memory encoding and retrieval [23, 24], and disruptions to these regions—common in TLE—are known to affect memory processes. Strategic and executive aspects of memory involve lateral prefrontal regions, inferior frontal gyrus, and medial frontal areas.

Alterations in these regions may impair retrieval monitoring and strategic search. The present findings align with this framework, showing redistributions of activity across frontal and posterior midline structures to compensate for impaired mesial temporal networks.

4.1.2. Verbal Memory

In verbal memory tasks, TLE patients demonstrated increased activation of the superior and middle frontal gyri during encoding and retrieval, indicating recruitment of executive and strategic processing regions to maintain performance. Activation of the left cingulate gyrus during retrieval suggests additional monitoring and attentional control. TLE patients showed reduced involvement of the lingual gyrus relative to healthy controls, which may reflect disrupted connectivity with temporo-occipital pathways. Overall, these results support a

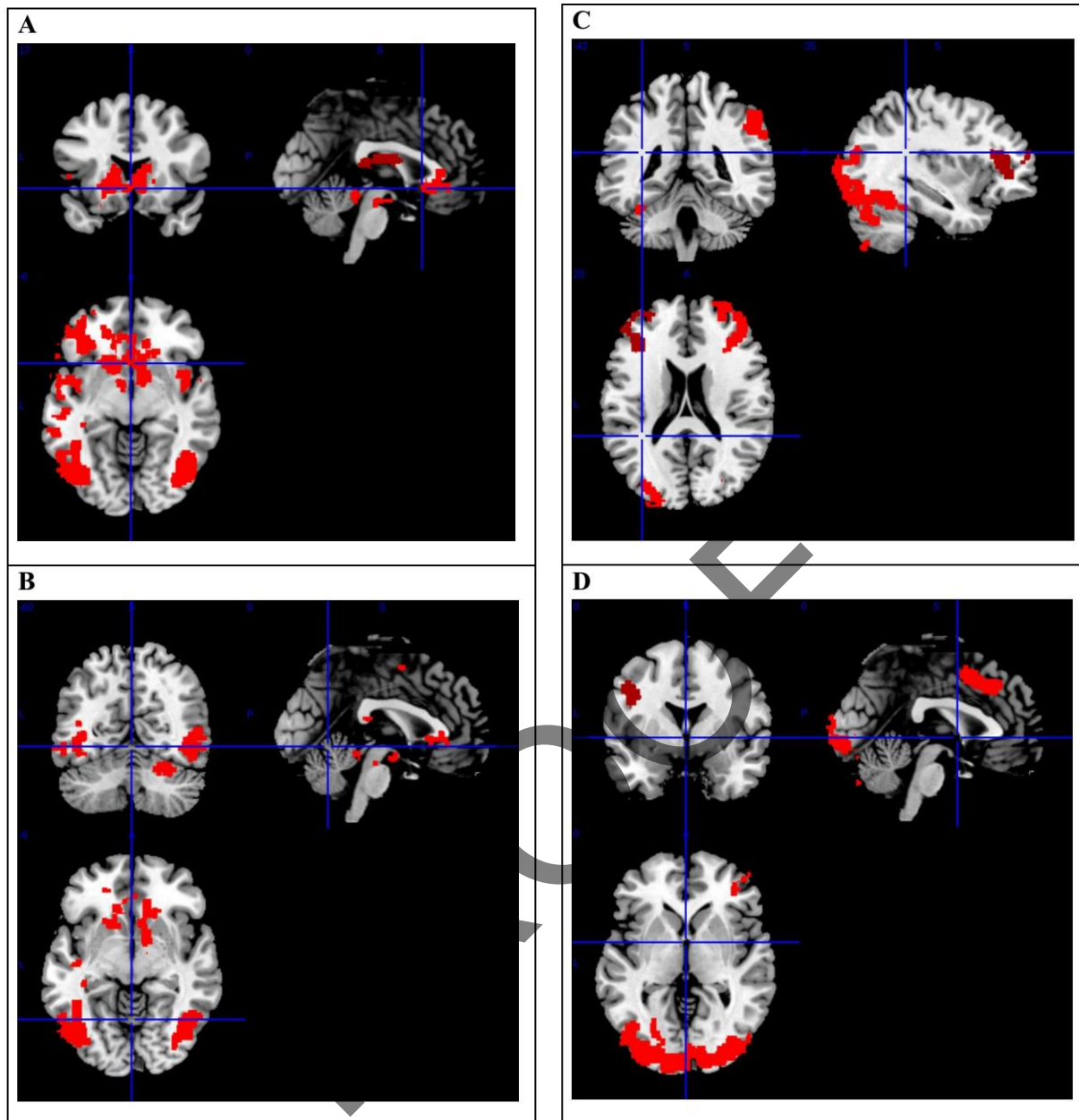


Figure 3. Cerebellum and Frontal Gyrus Activation in Memory and Language Processing in Both HC and TLE Patient Groups (A): Scene Picture Retrieval (HC>TLE). (B): Concrete Picture Retrieval (left-TLE> right-TLE). (C): Semantic Verbal Fluency> Passive Listening (HC). (D): Semantic Verbal Fluency> Passive Listening (left-TLE)

compensatory shift from canonical medial temporal and ventral visual pathways toward fronto-cingulate networks to preserve verbal memory performance under epileptic conditions.

4.2. Language Task

Language tasks elicited broader and more bilateral activation in TLE patients compared with HCs, particularly within the cerebellum, inferior frontal

gyrus, supplementary motor area, and posterior cingulate cortex. This widespread recruitment reflects functional reorganization to support preserved language abilities in the presence of chronic temporal lobe dysfunction. Prior studies have demonstrated the utility of semantic, receptive, and expressive fMRI paradigms for presurgical mapping [25-37]. Our language tasks, adapted from established clinical protocols, revealed overlapping activation patterns across HC, LTLE, and RTLE groups, with

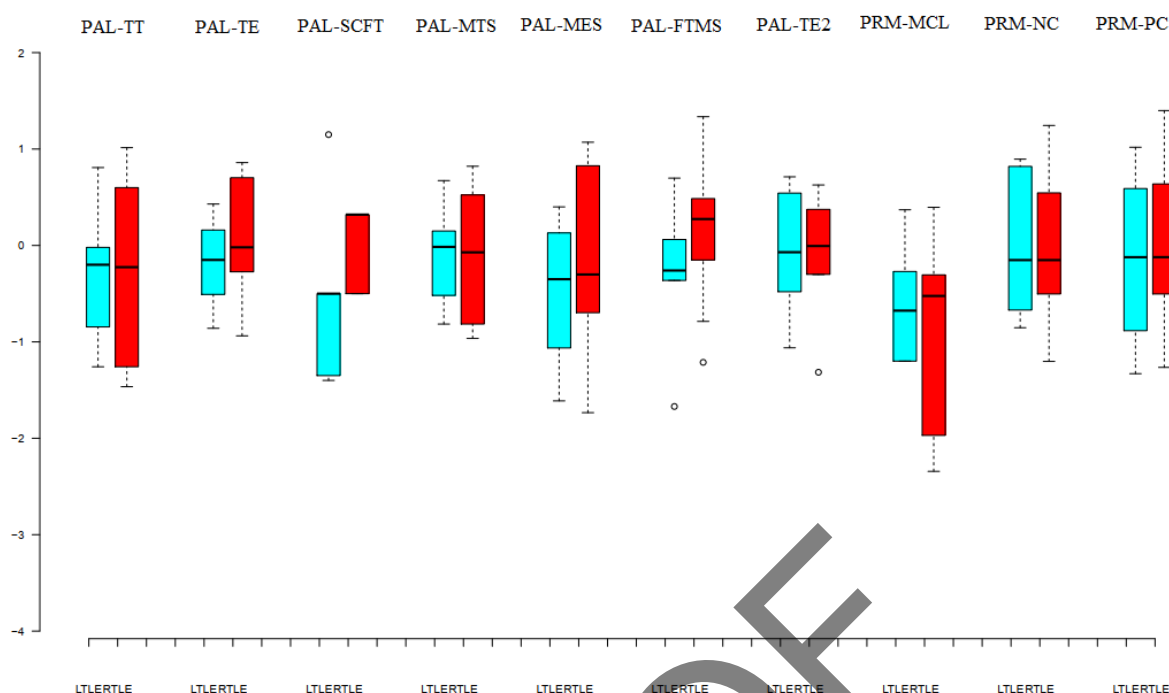


Figure 4. Box plot representation of the z-score value of CANTAB PAL and PRM tests. The red stars denote significant differences between the two groups (t-test p-value < 0.05). PAL Total trials (PAL-TT), PAL Total errors (PAL-TE), PAL Stages completed on the first trial (PAL-SCFT), PAL Mean trials to success (PAL-MTS), PAL Mean errors to success (PAL-MES), PAL First trial memory score (PAL-FTMS), PAL Total errors2 (PAL-TE2), PRM Mean correct latency (PRM-MCL), PRM Number correct (PRM -NC), and PRM Percent correct (PRM-PC)

Table 4. mean and standard deviation of z-score values for Neuropsychological tests

	PAL-TT	PAL-TE	PAL-SCFT	PAL-MTS	PAL-MES	PAL-FTMS	PAL-TE2	PRM-MCL	PRM-NC	PRM-PC
Mean	-0.30	-0.04	-0.20	-0.12	-0.31	-0.01	-0.06	-0.92	-0.02	-0.03
STD	0.82	0.56	0.68	0.60	0.88	0.77	0.57	1.05	0.69	0.78

Table note: PAL Total trials (PAL-TT), PAL Total errors (PAL-TE), PAL Stages completed on the first trial (PAL-SCFT), PAL Mean trials to success (PAL-MTS), PAL Mean errors to success (PAL-MES), PAL First trial memory score (PAL-FTMS), PAL Total errors2 (PAL-TE2), PRM Mean correct latency (PRM-MCL), PRM Number correct (PRM -NC), and PRM Percent correct (PRM-PC).

subtle distinctions in right-TLE patients. Passive listening consistently activated the superior temporal gyrus in both groups, while semantic fluency engaged fusiform and frontal regions. These findings reinforce the notion that language networks in TLE reorganize across both hemispheres and recruit auxiliary regions such as the cerebellum.

4.3. Integrated language–memory network patterns

Across memory and language domains, we identified consistent engagement of occipital, parietal, frontal, and cerebellar regions in addition to classical temporal lobe structures. For non-verbal memory, the lingual gyrus and cuneus were involved in encoding, whereas retrieval engaged occipital and cerebellar regions. In verbal tasks, the cerebellum supported encoding, while the fusiform gyrus contributed to

retrieval. Comparison with prior studies confirms the involvement of PFC and MTL in memory encoding and retrieval and supports evidence that TLE patients rely more heavily on parahippocampal and frontal regions during memory tasks. Our data also align with previous reports showing differential engagement of visual versus verbal memory systems in TLE.

Cerebellar involvement across several language paradigms also supports growing evidence for cerebellar contributions to linguistic processing. The absence of significant differences between LTLE and RTLE patients during verbal fluency, passive listening, and verb generation tasks further supports similar broad-level language network reorganization in both groups, in line with earlier reports.

4.4. Laterality (LTLE vs RTLE)

Although TLE laterality is often expected to lead to divergent patterns of functional reorganization, our findings revealed more similarities than differences between LTLE and RTLE across memory and language tasks. Direct contrasts did not show significant group-level differences ($P > 0.05$), indicating that both groups relied on similarly widespread bilateral networks. Exploratory contrasts revealed that LTLE patients occasionally showed greater frontal and cingulate recruitment during memory retrieval, while RTLE patients exhibited more occipital and parietal activation in some tasks. However, these effects were inconsistent and did not survive strict correction thresholds, suggesting that laterality-specific changes were secondary to the broader pattern of bilateral compensation. Neuropsychological measures also did not differ significantly between groups, supporting the interpretation that both LTLE and RTLE patients achieved cognitive performance through convergent compensatory strategies.

4.5. Interpretation and Clinical Relevance

The overarching pattern across all tasks indicates that TLE patients engage wider, bilateral, and more heterogeneous cortical networks than healthy controls. This reflects adaptive functional reorganization supporting preserved memory and language performance despite structural injury. These findings reinforce the concept that cognitive functions in TLE

are not restricted to canonical temporal structures but are distributed across extended networks that include frontal, parietal, midline, and cerebellar regions.

For clinical practice, these results underscore the value of integrated language–memory fMRI paradigms for presurgical evaluation. Broader activation patterns may indicate greater functional reserve or network flexibility, which could influence surgical decision-making. While our cross-sectional study cannot determine predictive validity, identifying compensatory recruitment patterns may help clinicians evaluate potential cognitive risks of resection. Longitudinal postoperative studies will be necessary to establish the prognostic utility of these activation patterns.

4.6. Limitations

This study has several limitations. The sample size was modest, particularly for the right-TLE group ($n = 14$), which may limit statistical power for laterality-specific analyses. The cross-sectional design prevents causal or longitudinal interpretation of reorganization. Recruitment from a single center may limit generalizability. Future studies should include larger, multi-center cohorts with balanced laterality groups and should incorporate longitudinal postoperative assessments. Integration of complementary modalities—such as diffusion imaging, resting-state fMRI, or intracranial EEG—would provide a more comprehensive understanding of network reorganization in TLE (Table 5).

5. Conclusion

This study shows that patients with temporal lobe epilepsy can maintain cognitive function through remarkably adaptive neural reorganization. Across memory and language tasks, they consistently engaged broader yet purposeful networks in the temporal, frontal, and cerebellar regions, indicating that the TLE brain preserves performance by flexibly redistributing cognitive workload. Using established clinical fMRI protocols and a data-driven analytic approach, we highlight distinct and meaningful patterns of reorganization across cognitive domains. These findings have important clinical relevance, offering improved guidance for presurgical functional

Table 5. Comparison the findings of the current study with previous studies

Paper and Task's type	Brain activation regions
[38] Sternberg memory task (evaluating working memory)	Memory Task TLE patients > HC → Abnormal activity of frontoparietal regions
[39] Visual Scenes Study (visual scenes versus a visual control condition of “scrambled” scenes) Words and Pictures Study 1. Hometown, block design. 2. Scenes, block design. 3. Scenes, event-related design. 4. Pictures, block design. 5. Pictures, event-related design. 6. Words, block design. 7. Words, event-related design	Memory Task TLE patients > Healthy → Bilateral medial temporal
[40] Language task Passive listening Memory task 2-back memory task Executive Task Congruent task Incongruent task	Memory Task TLE patients > HC → bilateral anterior, cingulate gyrus, bilateral wedge anterior lobe Language Task TLE patients > HC → right prefrontal lobe, the lateral temporal gyri, left cerebellum, left cornu laterale gyrus, left precuneus, the left postcentral gyrus Executive Task TLE patients > HC → right prefrontal, right frontal lobe, right brain, left superior temporal gyrus, right cerebellum anterior lobe
[41] Verbal and Non-verbal Tasks	Memory Task Left-TLE > HC → right medial temporal lobe Right-TLE < HC → Right hippocampus, right parahippocampus
Current Study Language Tasks PL SVF PVF VG	Memory Tasks HC > TLE Concrete Picture Encoding → L-FL Scene Picture Encoding → R-FUG Concrete Picture Retrieval → Left post-central gyrus Scene Picture Retrieval → L-IFG, L-IPL, R-OCL, R-PL, L-MFG

	Concrete Word Encoding → L-LIG
	Abstract Word Encoding → R-LIG
	Concrete Word Retrieval → -
	Abstract Word Retrieval → R-LIG, L-IPL, L-SPL
	<u>TLE > HC</u>
	Concrete Picture Encoding → L-TL, R-CU, L-PHC
	Scene Picture Encoding → L-PHC
	Concrete Picture Retrieval → L-LIG, L-P
	Scene Picture Retrieval → R-PHC
	Concrete Word Encoding → R-FL
	Abstract Word Encoding → L-FL
	Concrete Word Retrieval → L-CIG
	Abstract Word Retrieval → R-IOCG, R-SFG
	<u>Left-TLE > Right-TLE</u>
	Concrete Picture Encoding → L-CIG, L-FUG, R-FUG, L-IPL
	Scene Picture Encoding → R-FUG
	Concrete Picture Retrieval → R-FL, L-FL, L-MFG, R- CBM, L-FL, R-UN
	Scene Picture Retrieval → L-IFG
	Concrete Word Encoding → R-LIG
	Abstract Word Encoding → -
	Concrete Word Retrieval → L-LIG
	Abstract Word Retrieval → -
	<u>Right-TLE > Left-TLE</u>
	Concrete Picture Encoding → L-CU, L-PCL
	Scene Picture Encoding → -
	Concrete Picture Retrieval → R-PCIG
	Scene Picture Retrieval → L-CBM, L-FL
	Concrete Word Encoding → R-TL
	Abstract Word Encoding → R-CU, L-INS
	Concrete Word Retrieval → L-CIG, R-IOCG
	Abstract Word Retrieval → -

Current Study

Memory Tasks

- Scene picture encoding
- Concrete picture encoding
- Scene picture retrieval
- Concrete picture retrieval
- Abstract word encoding
- Concrete word encoding
- Abstract word retrieval
- Concrete word retrieval

mapping and more personalized surgical decision-making. Although preoperative fMRI mapping can guide surgical planning and may help predict

postoperative cognitive outcomes, longitudinal validation with postoperative outcome data is required to confirm predictive utility.

Acknowledgment

The authors recognize the significant contribution of the Iranian National Brain Mapping Laboratory (NBML), Tehran, Iran, for data acquisition services. Also, the authors would like to acknowledge support from the Iran Cognitive Sciences & Technologies Council. This work was partially funded and supported by the Cognitive Sciences & Technologies Council (Grant No. 6431), between 2017 and 2021.

The data supporting the findings of this study are available upon formal request.

The study was approved by the Research Ethics Board (Institutional Review Board, IRB) of Tehran University of Medical Sciences, and all participants provided informed consent.

References

- 1- Samuel Wiebe, Warren T Blume, John P Girvin, and Michael Eliasziw, "A randomized, controlled trial of surgery for temporal-lobe epilepsy." *New England Journal of Medicine*, Vol. 345 (No. 5), pp. 311–18, (2001).
- 2- Christoph Stippich *et al.*, "Localizing and lateralizing language in patients with brain tumors: feasibility of routine preoperative functional MR imaging in 81 consecutive patients." *Radiology*, Vol. 243 (No. 3), pp. 828–36, (2007).
- 3- Thomas Benke *et al.*, "Language lateralization in temporal lobe epilepsy: a comparison between fMRI and the Wada Test." *Epilepsia*, Vol. 47 (No. 8), pp. 1308–19, (2006).
- 4- Jozsef Janszky, Markus Mertens, Imre Janszky, Alois Ebner, and Friedrich G Woermann, "Left-sided interictal epileptic activity induces shift of language lateralization in temporal lobe epilepsy: an fMRI study." *Epilepsia*, Vol. 47 (No. 5), pp. 921–27, (2006).
- 5- Hennric Jokeit, Michael Okujava, and Friedrich G Woermann, "Carbamazepine reduces memory induced activation of mesial temporal lobe structures: a pharmacological fMRI-study." *BMC neurology*, Vol. 1 (No. 1), p. 6, (2001).
- 6- Hennric Jokeit, Michael Okujava, and Friedrich G Woermann, "Memory fMRI lateralizes temporal lobe epilepsy." *Neurology*, Vol. 57 (No. 10), pp. 1786–93, (2001).
- 7- M Schacher *et al.*, "Amygdala fMRI lateralizes temporal lobe epilepsy." *Neurology*, Vol. 66 (No. 1), pp. 81–87, (2006).
- 8- Leun J Otten, Richard NA Henson, and Michael D Rugg, "Depth of processing effects on neural correlates of memory encoding: relationship between findings from across-and within-task comparisons." *Brain*, Vol. 124 (No. 2), pp. 399–412, (2001).
- 9- HW Robert Powell, Matthias J. Koepp, Mark P Richardson, Mark R Symms, Pam J Thompson, and John S Duncan, "The application of functional MRI of memory in temporal lobe epilepsy: a clinical review." *Epilepsia*, Vol. 45 (No. 7), pp. 855–63, (2004).
- 10- César Ávila *et al.*, "Memory lateralization with 2 functional MR imaging tasks in patients with lesions in the temporal lobe." *American journal of neuroradiology*, Vol. 27 (No. 3), pp. 498–503, (2006).
- 11- Endel Tulving, Shitu Kapur, FI Craik, Morris Moscovitch, and Sylvain Houle, "Hemispheric encoding/retrieval asymmetry in episodic memory: positron emission tomography findings." *Proceedings of the National Academy of Sciences*, Vol. 91 (No. 6), pp. 2016–20, (1994).
- 12- Paul J Reber and Larry R Squire, "Parallel brain systems for learning with and without awareness." *Learning & memory*, Vol. 1 (No. 4), pp. 217–29, (1994).
- 13- Marvin M Chun and Elizabeth A Phelps, "Memory deficits for implicit contextual information in amnesic subjects with hippocampal damage." *Nature neuroscience*, Vol. 2 (No. 9), pp. 844–47, (1999).
- 14- Haline E Schendan, Meghan M Searl, Rebecca J Melrose, and Chantal E Stern, "An fMRI study of the role of the medial temporal lobe in implicit and explicit sequence learning." *Neuron*, Vol. 37 (No. 6), pp. 1013–25, (2003).
- 15- Teena D Moody, Susan Y Bookheimer, Zeba Vanek, and Barbara J Knowlton, "An implicit learning task activates medial temporal lobe in patients with Parkinson's disease." *Behavioral neuroscience*, Vol. 118 (No. 2), p. 438, (2004).
- 16- Wei-Chun Wang, Michele M Lazzara, Charan Ranganath, Robert T Knight, and Andrew P Yonelinas, "The medial temporal lobe supports conceptual implicit memory." *Neuron*, Vol. 68 (No. 5), pp. 835–42, (2010).
- 17- Lars Nyberg, "Levels of processing: A view from functional brain imaging." *Memory*, Vol. 10 (No. 5-6), pp. 345–48, (2002).
- 18- Sallie Baxendale, Pamela Thompson, William Harkness, and John Duncan, "Predicting memory decline following epilepsy surgery: a multivariate approach." *Epilepsia*, Vol. 47 (No. 11), pp. 1887–94, (2006).
- 19- Gordon J Chelune, "Hippocampal adequacy versus functional reserve: predicting memory functions following temporal lobectomy." *Archives of Clinical Neuropsychology*, Vol. 10 (No. 5), pp. 413–32, (1995).
- 20- Tatia Lee, James TH Yip, and Marilyn Jones-Gotman, "Memory deficits after resection from left or right anterior

- temporal lobe in humans: a meta-analytic review." *Epilepsia*, Vol. 43 (No. 3), pp. 283–91, (2002).
- 21- Daniel L Drane, "Understanding Working Memory Recovery Following Anterior Temporal Lobe Resection." *Epilepsy currents*, Vol. 15 (No. 1), pp. 17–19, (2015).
- 22- Nicholas M Thompson, Carien M van Reekum, and Bhismadev Chakrabarti, "How cognitive and affective empathy relate to emotion regulation: divergent patterns from trait and task-based measures." *Biorxiv*, p. 611301, (2019).
- 23- Chris M Bird, "The role of the hippocampus in recognition memory." *Cortex*, Vol. 93pp. 155–65, (2017).
- 24- Y Lakshmisha Rao, B Ganaraja, BV Murlimanju, Teresa Joy, Ashwin Krishnamurthy, and Amit Agrawal, "Hippocampus and its involvement in Alzheimer's disease: a review." *3 Biotech*, Vol. 12 (No. 2), p. 55, (2022).
- 25- Jeffrey R Petrella *et al.*, "Preoperative functional MR imaging localization of language and motor areas: effect on therapeutic decision making in patients with potentially resectable brain tumors." *Radiology*, Vol. 240 (No. 3), pp. 793–802, (2006).
- 26- Maria Engström, Mattias Ragnehed, Peter Lundberg, and Birgitta Söderfeldt, "Paradigm design of sensory–motor and language tests in clinical fMRI." *Neurophysiologie Clinique/Clinical Neurophysiology*, Vol. 34 (No. 6), pp. 267–77, (2004).
- 27- Christopher F Benjamin *et al.*, "Presurgical language fMRI: Mapping of six critical regions." *Human brain mapping*, Vol. 38 (No. 8), pp. 4239–55, (2017).
- 28- Christopher FA Benjamin *et al.*, "Presurgical language fMRI: clinical practices and patient outcomes in epilepsy surgical planning." *Human brain mapping*, Vol. 39 (No. 7), pp. 2777–85, (2018).
- 29- Susan Bookheimer, "Pre-surgical language mapping with functional magnetic resonance imaging." *Neuropsychology review*, Vol. 17pp. 145–55, (2007).
- 30- Victoria L Ives-Deliperi, James T Butler, and Ernesta M Meintjes, "Functional MRI language mapping in pre-surgical epilepsy patients: findings from a series of patients in the Epilepsy Unit at Mediclinic Constantiaberg." *South African Medical Journal*, Vol. 103 (No. 8), pp. 563–67, (2013).
- 31- Melanie Genetti *et al.*, "Noninvasive language mapping in patients with epilepsy or brain tumors." *Neurosurgery*, Vol. 72 (No. 4), pp. 555–65, (2013).
- 32- Ali Mahdavi, Ramyar Azar, Majid Haghighat Shoar, Sina Hooshmand, Arash Mahdavi, and Homayoon Hadizadeh Kharrazi, "Functional MRI in clinical practice: Assessment of language and motor for pre-surgical planning." *The Neuroradiology Journal*, Vol. 28 (No. 5), pp. 468–73, (2015).
- 33- Sasan Partovi *et al.*, "Effects of covert and overt paradigms in clinical language fMRI." *Academic radiology*, Vol. 19 (No. 5), pp. 518–25, (2012).
- 34- Jerzy P Szaflarski *et al.*, "Practice guideline summary: Use of fMRI in the presurgical evaluation of patients with epilepsy: Report of the Guideline Development, Dissemination, and Implementation Subcommittee of the American Academy of Neurology." *Neurology*, Vol. 88 (No. 4), pp. 395–402, (2017).
- 35- John L Ulmer *et al.*, "Lesion-induced pseudo-dominance at functional magnetic resonance imaging: implications for preoperative assessments." *Neurosurgery*, Vol. 55 (No. 3), pp. 569–81, (2004).
- 36- Stephen M Wilson, Alexa Bautista, Melodie Yen, Stefanie Lauderdale, and Dana K Eriksson, "Validity and reliability of four language mapping paradigms." *NeuroImage: Clinical*, Vol. 16pp. 399–408, (2017).
- 37- Shruti Agarwal, Haris I Sair, Sachin Gujar, and Jay J Pillai, "Language mapping with fMRI: current standards and reproducibility." *Topics in Magnetic Resonance Imaging*, Vol. 28 (No. 4), pp. 225–33, (2019).
- 38- Alfonso Fajardo-Valdez, Vicente Camacho-Téllez, Raúl Rodríguez-Cruces, María Luisa García-Gomar, Erick Humberto Pasaye Alcaraz, and Luis Concha, "Functional Correlates of Cognitive Performance and Working Memory in Temporal Lobe Epilepsy: Insights from Task-based and Resting-state fMRI." *medRxiv*, p. 2022.08.02.22278343, (2022).
- 39- Karren Towgood *et al.*, "Bringing memory fMRI to the clinic: comparison of seven memory fMRI protocols in temporal lobe epilepsy." *Human brain mapping*, Vol. 36 (No. 4), pp. 1595–608, (2015).
- 40- Lili Guo, Genji Bai, Hui Zhang, Daoyan Lu, Jiyong Zheng, and Gang Xu, "Cognitive functioning in temporal lobe epilepsy: a BOLD-fMRI study." *Molecular neurobiology*, Vol. 54pp. 8361–69, (2017).
- 41- Sarah Jane Banks, Viviane Sziklas, Devin J Sodums, and Marilyn Jones-Gotman, "fMRI of verbal and nonverbal memory processes in healthy and epileptogenic medial temporal lobes." *Epilepsy & Behavior*, Vol. 25 (No. 1), pp. 42–49, (2012).

Supplements

Table S1. Comparison of the TLE patient group with the Healthy Control group in Language

Group	Language Task	Cluster region	Cluster size (Voxels)	Z Score
HC		R. Precentral gyrus	3261	3.65
		L. Superior temporal gyrus	3095	3.96
TLE	PL	L. Superior temporal gyrus	8583	5.84
		R. Superior temporal gyrus	7970	7.21
		Cerebellum	1259	4.42
		R. Cerebellum	1107	6.09
		R. Superior frontal gyrus	746	4.13
HC > TLE		----	----	----
TLE > HC		----	----	----
HC		L. Cerebellum	12279	5.15
		R. Middle frontal gyrus	2108	4.17
		L. Middle frontal gyrus	1324	3.51
TLE	SVF	L. Cerebellum	17616	6.63
		R. Inferior frontal gyrus	4998	5.24
		L. Inferior frontal gyrus	2188	5.26
		R. Superior parietal lobe	530	3.48
HC > TLE		-----	-----	-----
TLE > HC		-----	-----	-----
HC		L. Cingulate gyrus	45645	4.69
TLE		L. Lingual gyrus	54613	5.83
HC > TLE	PVF	L. Inferior frontal gyrus	1510	3.37
		L. Precuneus	679	3.26
		L. Cerebellum	646	3.72
		L. Middle frontal gyrus	584	3.23
TLE > HC		R. Posterior cingulate	1447	3.97
HC		L. Inferior frontal gyrus	23547	5.31
		R. Cerebellum	4803	4.81
		L. Inferior parietal lobe	2218	4
TLE	VG	Cerebellum	10357	4.89
		L. Frontal lobe	3496	4.17
HC > TLE		-----	-----	-----
TLE > HC		-----	-----	-----

PL: passive listening; SVF: semantic verbal fluency; PVF: phonetic verbal fluency; VG: verb generation; HC: healthy control; TLE: temporal lobe epilepsy; R: right; L: left

Table S2. Comparison of the left-TLE and right-TLE groups in Language Task

Group	Language Task	Cluster region	Cluster size (Voxels)	Z Score
Left-TLE	PL	R. Superior temporal gyrus	6220	5.98
		L. Superior temporal gyrus	6207	5.2
		Cerebellum	1309	5.14
		L. Middle frontal gyrus	1020	3.79
		L. Cerebellum	962	4.12
	SVF	R. Cerebellum	14022	5.48
		R. Insula	1824	4.54
		L. Inferior frontal gyrus	1233	4.36
	PVF	R. Cingulate gyrus	30111	4.79
		R. Cerebellum	2797	4.67
	VG	Cerebellum	2172	4.08
		Cerebellum	1711	4.09
		L. Temporal lobe	1105	3.81
		L. Thalamus	1063	3.65
Right-TLE	PL	L. Middle temporal gyrus	3302	4.39
		R. Superior temporal gyrus	2214	4.2
	SVF	L. Cerebellum	5533	4.29
		R. Middle frontal gyrus	1522	4.3
	PVF	R. Putamen	9828	4.12
		R. Temporal lobe	7965	3.85
		L. Superior parietal lobule	635	3.38
	VG	L. Inferior frontal gyrus	1109	3.49
		L. Cerebellum	918	3.48
		L. Superior parietal lobule	826	3.66

PL: passive listening; SVF: semantic verbal fluency; PVF: phonetic verbal fluency; VG: verb generation; TLE: temporal lobe epilepsy; R: right; L: left

Table S3. Comparison of the Language Tasks across Left-TLE, Right-TLE, and Healthy Control cohorts

Group	Language Task	Cluster region	Cluster size (Voxels)	Z Score	
HC	PL > SVF	R. Precentral gyrus	8354	4.46	
		L. Precentral gyrus	6025	4.39	
		Frontal lobe	1076	3.24	
		L. Precuneus	530	3.39	
	SVF > PL	L. Fusiform gyrus	5152	3.9	
		R. Middle frontal gyrus	3154	3.72	
		R. Temporal lobe	1317	3.39	
		R. Inferior parietal lobe	1152	3.6	
		L. Frontal lobe	729	3.74	
		L. Middle frontal gyrus	512	3.53	
	VG > PVF	-----	-----	-----	
	PVF > VG	L. Anterior cingulate gyrus	567	3.77	
	Left-TLE	PL > SVF	R. Superior temporal gyrus	8145	5.44
L. Superior temporal gyrus			7587	4.97	
L. Precuneus			1825	4.76	
R. frontal lobe			1549	4.29	
SVF > PL		L. Fusiform gyrus	11723	4.85	
		R. Middle frontal gyrus	1388	4.04	
		R. Medial frontal gyrus	931	3.96	
		L. Precentral gyrus	628	3.91	
		R. Precuneus	625	3.52	
VG > PVF		-----	-----	-----	
Right-TLE		PL > SVF	L. Superior temporal gyrus	3779	4.07
			R. Superior temporal gyrus	3670	4.36
			L. Angular gyrus	765	3.42
	SVF > PL	L. Cerebellum	2316	3.72	
		R. Superior frontal gyrus	2095	4.26	
	VG > PVF	-----	-----	-----	
	PVF > VG	R. Caudate nucleus	1330	3.27	

PL: passive listening; SVF: semantic verbal fluency; PVF: phonetic verbal fluency; VG: verb generation; HC: healthy control; TLE: temporal lobe epilepsy; R: right; L: left.

Table S4. Power analysis by Cohen’s method for a two-tail t-test (comparison of differences between two independent means) for each brain structure showing significantly different z-scores in a functional task. A post-hoc analysis was performed using G*Power S/W to compute achieved power given the significance level ($\alpha=0.05$) and the sample size in each comparison group. An effect size was computed beforehand for the average z-scores within each activated region

Comparison	Significantly different activation pattern
TLE (N=35) vs. HC (N=17)	Lingual gyrus in Concrete Picture Encoding TLE: average number of voxels: 1148, average z-score: 2.64 HC: average number of voxels: 8815, average z-score: 4.42 Effect size: 1.78, Power: 0.99
	Cerebellum in Abstract in Word Encoding TLE: average number of voxels: 1821, average z-score: 1.37 HC: average number of voxels: 11715, average z-score: 2.37 Effect size: 1, Power: 0.91
	Cerebellum in Semantic in Verbal Fluency TLE: average number of voxels: 17616, average z-score: 3.63 HC: average number of voxels: 12279, average z-score: 2.15 Effect size: 1.48, Power: 0.99
	Superior Temporal Gyrus in Passive Listening TLE: average number of voxels: 8583, average z-score: 3.84 HC: average number of voxels: 3095, average z-score: 1.96 Effect size: 1.88, Power: 0.99
	Frontal Gyrus in Verb Generation TLE: average number of voxels: 3496, average z-score: 1.17 HC: average number of voxels: 23547, average z-score: 2.31 Effect size: 1.14, Power: 0.96
	Cerebellum Concrete Picture Encoding L-TLE: average number of voxels: 16119, average z-score: 2.6 R-TLE: average number of voxels: 15749, average z-score: 1.63 Effect size: 0.97, Power: 0.77
L-TLE (N=21) vs. R-TLE (N=14)	Cerebellum Concrete Word Encoding L-TLE: average number of voxels: 9727, average z-score: 2.89 R-TLE: average number of voxels: 2341, average z-score: 1.06 Effect size: 1.83, Power: 0.99
	Cerebellum in Semantic Verbal Fluency L-TLE: average number of voxels: 14022, average z-score: 2.48 R-TLE: average number of voxels: 5533, average z-score: 1.29 Effect size: 1.19, Power: 0.91
	Superior Temporal Gyrus in Passive Listening L-TLE: average number of voxels: 6220, average z-score: 2.98 R-TLE: average number of voxels: 2214, average z-score: 1.2 Effect size: 1.78, Power: 0.99
	Cerebellum in Verb Generation L-TLE: average number of voxels: 2172, average z-score: 2.08 R-TLE: average number of voxels: 918, average z-score: 1.48 Effect size: 0.6, Power: 0.39